

BINDURA UNIVERSITY OF SCIENCE EDUCATION

FACULTY OF SCIENCE

DEPARTMENT OF OPTOMETRY

Innovative Approaches in Early Diagnosis of Keratoconus:

A Comparative study of Diagnostic tools in Harare, Zimbabwe

By

Jerad Weale

B232153B

A thesis submitted in partial fulfillment of the requirements of the degree of

BSc Honours Optometry OPTC 405

Supervisor:	Dr Mashoko
Co-Supervisor:	Dr Ron Mhizha/ Dr Sachin Bawa

DECLARATION

I, Jerad Weale, declare that the contents of this thesis represent my own unaided work, and that the thesis has not previously been submitted for academic examination towards any qualification. Furthermore, it represents my own opinions and not necessarily those of the University of Bindura.



_____ Date: ____31/05/2026_____

Jerad Weale

DEDICATION

This dissertation is dedicated to my mother, Shelima Murad Weale and brother, Fadil Weale , who have been constant pillars throughout my life and especially in my academic career.

ACKNOWLEDGEMENT

I would like to express my extreme gratitude to my supervisors Dr Mashoko, Dr Ron Mhizha and Dr Sachin Bawa for their unwavering academic guidance and mentorship throughout this journey. I am also incredibly thankful to The Eye Institute, Zimbabwe and I-Surgeon , South Africa , who availed their resources, staff and equipment to complete my study .

I extend my gratitude to Medlane Day Hospital for their support during this period .

Lastly , to my partner Anita, family, friends and colleagues , your love and support carried me through the challenging and demanding times , and I am forever grateful.

ABSTRACT

Background: *Keratoconus is a progressive, non-inflammatory corneal ectatic disorder characterized by corneal thinning, corneal steepening, and gradual visual impairment. Early diagnosis is essential to prevent disease progression and preserve vision through timely intervention, such as corneal cross-linking. Recent advances in corneal tomography and multimodal imaging offer improved diagnostic capabilities by combining structural and biomechanical assessments. However, evidence comparing these diagnostic approaches in resource-limited settings such as Zimbabwe remains limited.*

Objective: *This study compared the diagnostic accuracy of corneal topography, corneal tomography, and multimodal imaging for the early detection of keratoconus among patients attending eye care facilities in Harare, Zimbabwe, and evaluated their suitability for routine clinical use.*

Methods: *A comparative cross-sectional study was conducted involving 30 participants (60 eyes), categorized into normal, keratoconus suspect, and confirmed keratoconus groups. Participants underwent comprehensive ocular examinations, including visual acuity assessment, pachymetry, keratometry, corneal topography, corneal tomography, and multimodal imaging. Diagnostic performance was evaluated by comparing the ability of each modality to detect early and subclinical keratoconus. Correlation and regression analyses were performed to determine the relationship between corneal thickness and curvature.*

Results: *Progressive corneal thinning and increasing corneal curvature were observed with advancing keratoconus. A statistically significant moderate negative correlation existed between corneal thickness and keratometry values ($r = -0.56$, $p = 0.0012$), demonstrating that thinning was associated with increased corneal steepening. However, pachymetry alone explained only 32% of the variation in keratometry values, indicating that keratoconus is a multifactorial disease requiring comprehensive assessment. Considerable overlap between keratoconus suspect and early keratoconus groups reduced the diagnostic effectiveness of single-parameter techniques.*

Conclusion: *Multimodal imaging provides the highest diagnostic accuracy for the early detection of keratoconus and should be considered the preferred diagnostic approach where resources permit. In resource-constrained settings such as Zimbabwe, corneal tomography offers the most practical and effective standalone diagnostic tool, providing earlier detection than conventional topography while remaining more feasible for routine clinical practice.*

Keywords: *Keratoconus; Early diagnosis; Corneal topography; Corneal tomography; Multimodal imaging; Diagnostic accuracy; Pachymetry; Zimbabwe*

Contents

Turnitin Report i
Turnitin Report ii
DECLARATION iii
DEDICATION iv
ACKNOWLEDGEMENT v
ABSTRACT vi
ABBREVIATIONS xi
CHAPTER ONE 1
INTRODUCTION 1
1.1 Introduction 1
1.2 Background of the study 3
1.3 Problem statement 4
1.4 5
1.5 5
1.6 5
1.7 5
1.8 5
1.9 6
CHAPTER TWO 7
LITERATURE REVIEW 7
2.1 Introduction 7
2.2 7
2.3 Theoretical literature review 8
2.3.1 Theory of corneal biomechanics 8
2.3.2 Technology acceptance theory 9
2.4 10
2.4.1 Biomechanical assessment technologies 12
2.4.2 Anterior Segment Optical Coherence Tomography (AS-OCT) 13
2.4.5 Artificial Intelligence in Keratoconus Diagnostics 14
2.5 14
2.6 Chapter summary 15
CHAPTER THREE 17
RESEARCH METHODOLOGY 17
3.1 Introduction 17
3.2 Research design 17

3.3 Study population 18
3.4 Sample size and sampling procedure 19
3.5 Inclusion criteria 19
3.6 Exclusion criteria 20
3.7 Research instruments 20
3.8 Data collection procedures 21
3.9 Data analysis 21
3.10 Validity and reliability 22
3.11 Ethical considerations 22
3.12 Chapter summary 23
CHAPTER FOUR 24
RESULTS AND DATA ANALYSIS 24
4.1 Introduction 24
4.2 Response rate 24
4.3 Baseline characteristics of the study population 25
4.4 Corneal thickness distribution by diagnostic category 26
4.5 Comparative analysis of group means and variability across diagnostic categories 30
4.6 Keratometry distribution by diagnostic category (eye-level analysis, n = 60 eyes) 34
4.7 Relationship between corneal thickness and corneal curvature 37
4.7 Clinician & patient evaluation 40
4.8 Visual acuity distribution 44
4.10 Topography – Keratoconus suspect 47
4.11 Keratoconus imaging pachymetry 49
4.9 Chapter summary 51
CHAPTER FIVE 53
DISCUSSION, CONCLUSIONS, AND RECOMMENDATIONS 53
5.1 Introduction 53
5.2 Discussion of findings 53
5.2.2 Corrective measures taken in the study population 53
5.2.3 Correlation of corneal thickness with corneal curvature 54
5.3.2 Is it possible to detect keratoconus in eyes that are classified as normal with conventional topography by advanced imaging modalities? 56
5.3.3 To what extent is it practical and acceptable to use sophisticated diagnostic devices in the optometrist's office? 56
5.4 Hypothesis testing 57
5.4.1 Null hypothesis (H_0) 57

5.4.2 Alternative hypothesis (H_1) 57
5.5 Conclusions 57
5.6 Recommendations 58
5.6.1 Recommendations for clinical practice. 58
5.6.2 Policy and health planning recommendations 58
5.7 Chapter summary 59
References 60
Appendix 1: Questionaire 63
Appendix 2: Ethical Clearance 65
Approval Letter and Consent 66

ABBREVIATIONS

AS- OCT - Anterior Segment Ocular Coherence Tomography

OCT – Ocular Coherence Tomography

KC- Keratoconus

OD – Right Eye

OS- Left Eye

CXL- Crosslinking

K- Readings – Keratometry Reading

DMEK- Descemet Membrane Endothelial Keratoplasty

AI-Artificial Intelligence

ECM – Extracellulatr Matrix

BADD-D – Belin/Ambrosio Deviation

CBI – Corvis Biomechanical Index

TBI – Tomographic and Biomechanical Index

IQR- Interquartile Range

DEFINITION OF TERMS

Keratoconus — a progressive, non-inflammatory corneal ectasia characterized by localized thinning and conical protrusion of the cornea leading to irregular astigmatism and visual loss.

Ectasia — structural weakening and outward bulging of the cornea; used broadly for keratoconus and post-refractive surgery ectatic changes.

Scissoring reflex — a retinoscopy sign where the reflex splits into two blades, suggestive of

irregular astigmatism from keratoconus.

Corneal Topography — Placido-disc based mapping of the anterior corneal surface curvature; sensitive to anterior surface irregularities but does not measure posterior surface or thickness.

Corneal Tomography — 3-D imaging (e.g., Scheimpflug/Pentacam) that measures anterior and posterior elevation, pachymetry maps, and provides volumetric data. Considered the gold standard for early detection.

Pachymetry — measurement of corneal thickness (central and maps); thinning is a hallmark of keratoconus.

Anterior Elevation and Posterior Elevation — deviations of corneal surfaces from a best-fit reference surface; posterior elevation changes often precede anterior changes in early disease.
Kmax — maximum keratometry value (steepest curvature) on topography/tomography; used to stage severity and monitor progression.

Corneal Hysteresis — an IOP-dependent measure of corneal viscoelastic damping (from Ocular Response Analyzer); lower values suggest biomechanical weakness. MDPI
Epithelial Mapping — high-resolution OCT measurement of epithelial thickness; epithelial thinning/compensation patterns can mask stromal cones and aid early detection

KMax - Kmax refers to the maximum keratometry reading, which measures the steepest or most curved point on the front surface of your cornea. It is measured in diopters (D) and is the primary metric eye specialists use to determine the severity, stage, and progression of the disease

CHAPTER ONE

INTRODUCTION

1.1 Introduction

Keratoconus is a progressive, bilateral, non-inflammatory ectatic disorder of the cornea characterized by localized areas of thinning of the stromal tissue and protrusion of the cornea, leading to irregular astigmatism, myopia, and progressive vision loss (Rabinowitz, 1998). The disease usually starts in adolescence or early adulthood, and its progression is dependent on several factors, including genetic susceptibility, biomechanical susceptibility, and environmental factors, including chronic rubbing of the eyes and allergic eye disease (Gomes et al., 2015). Keratoconus is one of the most common corneal indications for transplantation in most parts of the world, especially in younger patients, and is a large clinical and socioeconomic problem. The pathogenesis of keratoconus is characterized by abnormalities in the stromal structure and biochemical changes. These include collagen fibril disorganisation, ECM degradation, oxidative stress, and a decrease in biomechanical stability, which lead to progressive corneal deformation (Galvis et al., 2015). These changes can take place years before clinical signs are noticed, and early diagnosis is one of the most pressing issues for modern practice today in ophthalmology and optometry.

Keratoconus in its early stages may have no symptoms or exhibit mild refractive changes that are similar to normal astigmatism. Subclinical disease is, therefore, often not caught by conventional diagnostic techniques, including keratometry and slit-lamp biomicroscopy. Delayed diagnosis could allow the disease to progress to later stages, when there is significant visual impairment and corneal scarring (Rabinowitz, 1998). Key advances in therapeutic interventions have shown that early intervention can stop disease progression and minimise the need for corneal transplantation (O'Brart, 2014), in particular with the development of corneal collagen cross-linking (CXL).

Thus, the early detection has become more and more important. Corneal topography historically was a landmark development in the diagnosis of keratoconus, providing a way to measure abnormalities of the anterior corneal surface. These typical signs include inferior

steepening, radial axis skewing, and bow-tie pattern asymmetry, resulting in better clinician diagnosis of manifest disease (Klyce, 2009). Topography, however, mainly assesses the anterior corneal surface; it may not be sensitive enough to detect early ectatic changes that are occurring on the posterior surface or in the stromal architecture. In recent times, keratoconus diagnosis has undergone a revolutionary change with the development of much newer technology. The Scheimpflug imaging system allows corneal tomography and, for the first time, a 3-D assessment of the anterior and posterior corneal surfaces alongside the pachymetry mapping. The use of diagnostic indices, like Belin–Ambrósio Deviation Index (BAD-D), has been proven to enhance the sensitivity of detecting early ectasia (Ambrósio et al., 2011). Furthermore, biomechanical assessment devices like Corvis ST and the Ocular Response Analyzer are able to provide data on corneal deformation response and biomechanical integrity, assessing structural weakness, even before the appearance of morphological alterations (Vinciguerra et al., 2016). Anterior segment optical coherence tomography (AS-OCT) has enhanced the diagnostic capability with epithelial thickness mapping as well. In early keratoconus, stromal irregularities can be masked by the epithelial remodelling, so some keratoconus can be identified via epithelial profile analysis but not topography (Reinstein et al., 2019).

More recently, artificial intelligence (AI) and machine learning systems have become promising diagnostic tools that are able to combine the complex data from tomography, topography, OCT, and biomechanical imaging to enhance diagnostic accuracy and to minimize observer variability (Kamiya et al., 2021). Although these developments have taken place, there are still gaps in the literature. There are some studies available that compare modalities individually or analyze only two technologies in a retrospective study. Comparative efficacy of corneal topography, tomography, biomechanical assessment of corneal properties, and multimodal imaging has not been assessed in a prospective study in a single clinical cohort. In addition, little is known about the potential of such high-end diagnostics in everyday practices, especially in resource-poor conditions. There is, however, a need to compare the modern methods of detecting keratoconus in its early stages, and this study aims to perform this comparison. The study will evaluate the sensitivity, specificity, and diagnostic correlation and assess the clinical utility to determine the best diagnostic approach for early and subclinical keratoconus.

1.2 Background of the study

The multifactorial nature of keratoconus is increasingly appreciated, with both genetic, biochemical, inflammatory, and biomechanical mechanisms playing a role. The disease process causes progressive stromal weakening and deformation at normal intraocular pressure that produces irregular corneal protrusion and vision loss (Galvis et al., 2015). Abnormalities like decreased collagen crosslinking, increased proteolytic enzyme activity, keratocyte apoptosis, and oxidative stress have been observed in corneal tissue by histopathological studies (Gomes et al. 2015). In the past, slit-lamp and keratometry were used for diagnosis. Clinical signs like Fleischer rings, Vogt striae, and Munson's sign are generally seen only in moderate or advanced disease and are not useful for early detection of keratoconus. The advent of computerised corneal topography greatly enhanced the diagnosis capability allowing quantitative assessment of anterior corneal curvature patterns (Klyce, 2009). Topography, however, is only sensitive to changes in anterior corneal surface elevations and is incapable of detecting posterior surface elevation abnormalities and subtle anterior and posterior pachymetry changes which frequently precede detectable anterior changes. Next, a novel imaging technique, corneal tomography, was introduced as a better diagnostic tool, which offered a full 3D analysis of the corneal structure. The Pentacam is a Scheimpflug based imaging system that can assess anterior elevation, posterior elevation, corneal thickness distribution and pachymetry progression indices simultaneously. These parameters are combined in the Belin–Ambrósio Enhanced Ectasia Display (BAD-D) which aids in the early detection of ectatic disease (Ambrósio et al., 2011). Posterior corneal elevation and progressive abnormal pachymetry are some of the earliest detectable signs of keratoconus (de Sanctis et al., 2008). Recently, interest has focused on biomechanical evaluation of cornea. The Corvis ST is a device that measures corneal deformation in response to a calibrated air puff, which gives information on corneal stiffness and viscoelastic properties.

Both the Corvis Biomechanical Index (CBI) and the Tomographic Biomechanical Index (TBI) have shown very good sensitivity and specificity for diagnosing forme fruste keratoconus and subclinical keratoconus (Vinciguerra et al., 2016). These are especially useful technologies, as often structural abnormalities may not be detectable until biomechanical weakening has already taken place. Optical coherence tomography (OCT) of the anterior segment (AS-OCT) is also gaining more significance in keratoconus diagnosis. The use of epithelial thickness mapping can reveal patterns of epithelial remodelling that occur as compensation for stromal irregularities.

Reinstein et al. (2019) found that epithelial thickness variability was higher in early keratoconus, indicating that mapping of the epithelium could be another marker for early detection of keratoconus. Another great leap forward in diagnostics of the cornea is the application of artificial intelligence and machine learning. AI algorithms can leverage vast amounts of information from various imaging modalities to detect patterns that are not discernible by humans. A deep learning system using Scheimpflug and OCT datasets have shown that they can be used to diagnose both manifest and subclinical keratoconus with a high degree of accuracy (Kamiya et al., 2021). The use of AI-based systems in clinical practice, however, has been limited in its implementation in everyday clinical practice, and its generalisability across different population groups is not yet sufficiently explored. While there is a growing number of diagnostic technologies available, little evidence exists of their relative effectiveness in the real-world clinical setting. Most studies examine technologies separately, rather than make prospective assessments of multimodal combinations in the same population of patients. Furthermore, the factors of cost, access, clinician usability and examination time are frequently missing from the analyses. There is, therefore, a need for complex comparative studies which not only address the diagnostic accuracy but also the practicality of implementing the new technologies into routine optometric practice. The aim of this study is to contribute to filling in these gaps by conducting a prospective comparative analysis of corneal topography, tomography, biomechanical assessment and multimodal imaging in order to detect keratoconus in its early stages.

1.3 Problem statement

Diagnosis of keratoconus is a major clinical challenge, and can be difficult and often late. Conventional diagnostic methods, especially corneal topography, are not able to detect subclinical or earlier disease, since structural and biomechanical changes can occur before any anterior corneal changes are apparent. A late diagnosis means that the disease can progress to causing visual loss and eventually corneal transplantation may be required. While newer technologies like tomography, biomechanical imaging, AS-OCT and AI-assisted technology show promise in terms of improved sensitivity, comparative diagnostic efficacy and real-world applicability in clinical practice, further research is needed to establish these parameters. The absence of evidence also leads to variable diagnosis and can lead to missed opportunities for early intervention.

1.4 Aim of the study

1. To evaluate the utility of corneal topography and corneal tomography and multimodal imaging in the early diagnosis of keratoconus.
2. To identify and quantify the sensitivity and specificity of corneal topography, tomography and multimodal imaging in early and subclinical keratoconus.
3. To evaluate the clinical utility and feasibility of the application of emerging diagnostic technologies in a clinical setting.
4. To compare the accuracy of a combined multimodal approach to diagnosis with the accuracy of single modality diagnosis.

1.5 Research questions

1. How sensitive and specific are corneal topography, tomography and multimodal imaging in the diagnosis of early and subclinical keratoconus?
2. Are advanced imaging modalities able to detect keratoconus when topography classifies the cornea as normal?
3. What is the uptake and potential of incorporating cutting-edge diagnostics into everyday optometric practice?
4. Is multimodal diagnostic approach more accurate than single modality assessment?
5. How user-friendly did each diagnostic tool prove to be for clinicians after use?

1.6 Hypotheses

1. Null Hypothesis (H_0) Multimodal imaging techniques are not different in diagnostic accuracy for early keratoconus compared to corneal topography and tomography.
2. Alternative Hypothesis (H_1) Multimodal imaging is more effective than single modality imaging modalities in the detection of early keratoconus.

1.7 Scope and delimitations

This study was specifically designed for the early and subclinical detection of keratoconus in a specific clinical population. The studies evaluated different diagnostic tools such as corneal topography, tomography, biomechanical evaluation, and multimodal imaging. This study did not assess long-term disease course or treatment outcomes after diagnosis. Limitations included: small sample size, limited availability of advanced diagnostic equipment, and patient variability in compliance, such as contact lens dropping out before imaging. Inter-rater reliability of the observer's interpretation of the image

1.8 Significance of the study

This study should make a huge impact on clinical care and research. The results could help to detect keratoconus earlier and more accurately, allowing for timely treatment like corneal cross-linking and preventing vision loss. The research also helped doctors choose the best and most convenient diagnostic procedures for everyday practice. The study supported multimodal diagnostic approaches and added to the body of evidence for the use of AI in the imaging of the cornea. In the long term, better diagnostic approaches could help to improve patient outcomes, optimize resource use, and lower the burden resulting from advanced keratoconus.

1.9 Chapter summary

This chapter described keratoconus as a progressive corneal ectatic disorder that presents with subtle early clinical symptoms and is a big challenge for early diagnosis. The chapter emphasized the need for early detection to halt the progression of disease and maintain visual function by early intervention, including corneal collagen crosslinking. The study reviewed the historical evolution of keratoconus diagnostic methods starting with conventional keratometry and corneal topography, then advanced to the newer diagnostic technologies, including corneal tomography, biomechanical assessment, anterior segment optical coherence tomography, and artificial intelligence (AI) based diagnostics.

The presentation showed that these technologies are more sensitive in diagnosis, however, there are concerns about comparability of effectiveness and practical use in everyday clinical practice. The chapter also briefly explained the research problem, which included the inability of the traditional methods of diagnosis in detecting early and subclinical keratoconus and limited comparative data on newer multimodal diagnostic methods. A clear presentation of aim, objectives, research questions, and research hypotheses guided research. Furthermore, the scope and delimitations of the study were determined, which included the use of a clinical population and focusing specifically on the early detection of keratoconus, with the limitation of the sample size, equipment availability, and patient compliance.

Lastly, the importance of the study was mentioned, highlighting the potential benefits it could provide for more precise diagnoses, guiding clinical decisions based on evidence, optimizing patient care, and informing future research into multimodal and AI-assisted keratoconus diagnosis. The literature relevant to the pathophysiology, diagnosis, and existing evidence for early detection techniques for keratoconus was reviewed in the next chapter.

CHAPTER TWO

LITERATURE REVIEW

2.1 Introduction

The purpose of this chapter is to provide a thorough review of the theoretical and empirical work on early diagnosis of keratoconus and a comparison of the performance of modern keratoconus diagnostic tools. The review covers the evolution of keratoconus diagnosis from traditional methods like keratometry and corneal topography to more sophisticated technologies such as corneal tomography, biomechanical assessment, anterior segment optical coherence tomography (AS-OCT), epithelial thickness mapping, multimodal imaging, and artificial intelligence (AI) diagnostic systems. The chapter also explores the theories behind the onset and course of keratoconus, such as corneal biomechanical instability and ectatic progression. These theories offer a scientific rationale for the impact of structural and functional changes in the cornea on diagnosis. Theoretical perspectives that address technology acceptance in clinical practice are also addressed to put the incorporation of advanced imaging systems into perspective with clinical practice. Furthermore, empirical literature from previous studies is critically analyzed to identify similarities, differences, strengths, and limitations of previous research. Special focus is given to research looking into sensitivity, specificity, diagnostic indices, and multimodal methods of early and subclinical keratoconus detection. The chapter also pinpoints the lack of in-depth studies comparing various modalities within the same clinical population, particularly among prospective studies. This forms the basis and motivation for the current research work and shows its contribution to ophthalmic and optometric research.

2.2 Purpose of literature review

This literature review aims to critically examine and integrate available information on the diagnosis of keratoconus, creating a theoretical and empirical basis for this study. The review allows the researcher to learn the development of diagnostic technologies, to see the relationship between variables in the research, and to evaluate the success of various diagnostic approaches. A literature review is important because it allows the researcher to fit the research into the context of scientific knowledge. Through the study of literature, the researcher can discern "what has been studied before," determine strengths and weaknesses of previous methodology, and develop areas of further research to address unanswered questions. The

review also helps in understanding fundamental points of keratoconus such as corneal biomechanics, abnormalities in posterior elevation, corneal epithelial remodelling, and multimodal imaging. By reading the theoretical and empirical literature, the researcher can explain the development of diagnostic technologies and the fact that some technologies might offer better diagnostic accuracy. Moreover, the literature review provides evidence for the study hypotheses and research question. The results of diagnosis sensitivity, specificity, and multimodal imaging, which were found previously, are critically evaluated and its superiority over the single modality is determined based on the current evidence. One of the other crucial roles of the literature review is to determine gaps in the research. The current literature tends to evaluate diagnostic modalities separately, or in retrospective study designs, with little certainty about effectiveness in clinical practice. This recognition of gaps is justification for the current study. Last, the literature review helps to inform the methodological approach of the study by providing information about variables, diagnostic indices, and methods utilized in previous studies. This will ensure that the present study is scientifically-based and adds value to the available knowledge.

2.3 Theoretical literature review

2.3.1 Theory of corneal biomechanics

The biomechanics of the cornea is the structure and mechanics of the cornea which enable it to retain its shape and resist deformation under intraocular pressure (IOP) (Roberts and Dupps, 2014). According to the biomechanical theory of keratoconus, the deterioration of stromal collagen fibre strength results in progressive thinning and protrusion of the cornea. This theory posits that biomechanical failure starts before any topographic abnormalities are seen. This is why early or subclinical keratoconus patients can be normal during routine clinical examinations even if they are suffering from underlying corneal instability (Vinciguerra et al., 2016). Thus, the first pathological changes can be a decrease in the stiffness of a cornea, and not any obvious morphologic changes. Dupps and Wilson (2006) showed that weakening the focus of corneal tissue will lead to a change in stress distribution across the cornea, which will lead to progressive ectasia. The theory emphasises the value of assessing the behaviour of corneal deformation, in addition to surface curvature analysis. Biomechanical theory has had a great impact on the evolution of diagnostic tools like the Corvis ST and the ORA. These devices measure corneal deformation under an air puff and generate parameters related to deformation amplitude, applanation velocity, and corneal stiffness (Vinciguerra et al., 2016). This

theoretical background led to the creation of the Corvis Biomechanical Index (CBI) and Tomographic Biomechanical Index (TBI), which have proven to be highly sensitive in detecting former fruste and subclinical keratoconus (Ambrósio et al., 2017). These indices can be developed based on biomechanical and tomographic data for early disease diagnosis. The biomechanical theory is of particular importance for the current study since it provides supporting evidence for the employment of multimodal imaging and for the fact that advanced imaging may be more useful than conventional topography in the diagnosis of early keratoconus. 2.3.2 Ectasia progression theory.

The progression theory of ectasia suggests that keratoconus is a progressive disease caused by a destabilisation of the cornea due to the interplay of genetic and biochemical, inflammatory, and environmental factors (Galvis et al., 2015). The theory is that the disease gradually progresses because the corneas are losing strength over time. It is important that in this theory, the posterior changes take place before the anterior surface changes. Thus, posterior elevation analysis and pachymetry progression measurements can help detect keratoconus prior to the appearance of clinical signs on anterior topography (de Sanctis et al., 2008). The theory also emphasises the role of oxidative stress and inflammatory mediators in stromal degeneration. The increased expression of inflammatory cytokines and Matrix Metalloproteinases leads to the degradation of collagen and biomechanical weakening of the cornea (Gomes et al., 2015).

Chronic rubbing of the eye and allergic eye disease are thought to worsen the disease by causing mechanical trauma and inflammation of the cornea (Ramos et al., 2012). This is why there is variability in the progression rate of keratoconus between people. The progression theory of ectasia argues for the use of advanced imaging technologies for assessment of posterior elevation, corneal thickness distribution and stromal architecture. Some of the technologies developed include Scheimpflug tomography and AS-OCT, developed in part to address evidence for the presence of early ecstatic changes below the anterior corneal surface. This theory thus forms a useful scientific framework to compare the diagnostic methods and test for the superiority of multimodal methods to detecting disease at an early stage.

2.3.2 Technology acceptance theory

Davis (1989) developed the Technology Acceptance Model (TAM) that addresses factors that affect the adoption and use of new technologies in the workplace. From the theory, perceived usefulness and perceived usefulness of ease are the main factors that determine the acceptance of technology. Research in healthcare has also demonstrated that the use of sophisticated

diagnostic technologies is more likely to be accepted by healthcare professionals when they believe that these technologies will lead to better patient outcomes, greater diagnostic accuracy and improved efficiency (Holden and Karsh, 2010). On the other hand, technologies that are considered to be more complicated, time consuming, or costly can have lower acceptance despite the clinical advantages. The theory is very applicable to the diagnosis of keratoconus because the newer technologies like tomography, biomechanical imaging, AI assisted technologies, etc. require specialized training and a high level of investment. So, clinicians may not be as inclined as others to make these technologies a part of their normal practice. Holden and Karsh (2010) found that user-friendliness and seamless integration of systems into clinical routines increase the likelihood of use of new technologies.

The interpretability and the speed of examination are therefore important considerations. The present research also involves a qualitative evaluation of the usability and usefulness of the diagnostic tools for the clinicians. It is directly related to the Technology Acceptance Model and allows to assess influence factors for the implementation of imaging systems. Hence, the concept of diagnostic effectiveness, usability, accessibility, and the integration of these technologies into workflow are crucial to the understanding of the adoption of modern keratoconus diagnostic technologies, and have been incorporated into the Technology Acceptance Theory.

2.4 Empirical literature review

The diagnosis of keratoconus is facilitated by corneal Topography.Cornal Topography plays an important role in the diagnosis of keratoconus. In the past, corneal topography has been the key element in the diagnosis of keratoconus. The technology evaluates anterior corneal curvature and creates colour coded maps which help the clinician detect abnormal corneal patterns (Klyce, 2009). Rabinowitz (1998) had previously shown that topographic indices like inferior–superior (I–S) asymmetry and keratometry steepening were significant factors in the diagnosis of manifest keratoconus. A series of features such as downgoing steepening, bow-tie patterns which are not symmetrical, and skewed radial axes were adopted as common features used in clinical diagnosis.

Compared to slit-lamp examination and keratometry, topography was a significant improvement as it was able to detect changes in the cornea prior to the development of obvious clinical changes such as Vogt striae or Fleischer rings. Maeda and Klyce (1995) also showed relative high sensitivity and specificity for distinguishing keratoconus from normal corneas

using the computer-assisted videokeratography. As such, corneal topography became a necessary part of the screening process for refractive surgery. Although these benefits were noted, later studies showed that there were serious restrictions in the ability to detect subclinical disease.

However, topography only measures the curvature of the anterior cornea and is unable to measure posterior corneal abnormalities or biomechanical corneal weakening that could occur before anterior curvature changes, as Klyce (2009) reported. De Sanctis et al. (2008) have shown that some eyes with normal Placido-disc topography had abnormal posterior elevation patterns on Scheimpflug tomography. This indicated that using anterior surface analysis techniques may miss the earliest signs of ectasia. Moreover, Salomão and Ambrósio (2020) reported that, in addition to topography-based screening, keratoconus should be tested by corneal aberrometry because topography alone may lead to an increased risk of missing forme fruste keratoconus and thus an increased risk of postoperative keratoconus (PKEK) after laser vision correction procedures.

In addition, tear film instability, fixation problems and warping of contact lenses can compromise topographic reliability and reproducibility. Despite being widely adopted due to its cost effectiveness and availability, there are various evidences that suggest topography is not an ideal diagnostic measure for early keratoconus detection. The cornea is the front surface of the eye.Corneal Tomography and Scheimpflug Imaging is the front surface of the eye. Corneal tomography was a significant development in the diagnosis of keratoconus, as it allows the anterior and posterior surface of the cornea to be evaluated in three dimensions as well as a map of the Pachymetry.

The Pentacam is a Scheimpflug imaging system that enables a comprehensive evaluation of the distribution of corneal elevation, curvature and thickness. This technology has helped the understanding of the posterior corneal abnormalities in early keratoconus (Belin and Khachikian, 2006). Tomography is a more comprehensive assessment of the cornea than topography, and assesses the whole cornea. This is especially relevant as posterior corneal elevation and irregular pachymetry changes can be observed prior to clinically identifiable irregularities in the anterior corneal surface. Ambrosio et al. (2011) created the Belin–Ambrosio Enhanced Ectasia Display (BAD-D) that combines anterior elevation, posterior elevation, progression of pachymetry, and relational thickness indices in a single diagnostic parameter.

The BAD-D had much higher sensitivity in detecting subclinical keratoconus and was widely accepted in the refractive surgery evaluation practices. Lopes et al. (2021) determined that tomographic evaluation of the pachymetry changes and the elevation of posterior surface was excellent for discriminating between normal corneas and early ectatic disease. The authors concluded that tomography should be used as part of the refractive surgery screening procedure since it will aid in detecting fine corneal instability which might otherwise go undiagnosed. Gomes et al. (2015) also emphasized the importance of tomography in the follow-up of the disease, especially for the assessment of candidates for corneal collagen cross-linking. Tomographic analysis further plays a role in disease staging like the ABCD keratoconus grading system, which takes into account anterior curvature, posterior curvature, pachymetry, and visual acuity for a more detailed assessment of the severity of the disease. However, research has indicated that structural imaging might still underestimate some of the earliest biomechanical abnormalities, which led to the combination of structural imaging with assessments of biomechanical technologies.

2.4.1 Biomechanical assessment technologies

The biomechanical assessment technologies measure the mechanical behavior and resistance to deformation of the cornea. Such devices can provide functional data on the stiffness and viscoelastic properties of the cornea that can complement structural imaging devices. The Ocular Response Analyzer (ORA) was one of the first technologies developed to assess biomechanics in vivo. Corneal hysteresis was introduced by Luce (2005) as a parameter which reflects the energy absorbed by the cornea and biomechanical integrity. Lower CH and CF values were always found to correlate with keratoconous cornea.

Later, the Corvis ST conducted biomechanical analysis by applying ultra-high-speed Scheimpflug imaging to capture the dynamic corneal deformation response to an air puff (Vinciguerra et al., 2016). This allowed for detailed analysis of the amplitude of deformation, applanation times, corneal velocity, and parameters of stiffness. These technologies are of growing significance in the early detection of disease due to biomechanical weakening that can precede progression to structural changes. Vinciguerra et al 2016 has proved the Corvis Biomechanical Index (CBI) to be very sensitive and specific for keratoconus detection including forme fruste.

Biomechanical abnormalities were frequently found before the obvious change on the tomograms, which indicates that biomechanical failure may occur prior to structural changes

during disease development. Ambrósio et al. (2017) later came up with the Tomographic Biomechanical Index (TBI) combining biomechanical and tomographic information with the help of artificial intelligence algorithms. Overall, the TBI showed better diagnostic performance than any modality individually and better detection of subclinical ectasia. These results strongly argue for multimodal diagnostic strategies and indicate that the combination of structural and functional evaluations results in better risk stratification and early diagnosis.

2.4.2 Anterior Segment Optical Coherence Tomography (AS-OCT)

Anterior segment optical coherence tomography (AS-OCT) is a high-resolution cross-sectional imaging technique of the cornea and anterior segment structures. The importance of the AS-OCT in keratoconus has grown in recent years due to its capacity to assess the pattern of epithelial thickness and the architecture of the stroma. Reinstein et al. (2019) have shown that stromal irregularity can be compensated for by changes in the epithelium and that these may not be apparent on topographic analysis of the cornea. In general, the epithelium is thinner on the apex of the cone and thicker in the annular area.

Epith thickness differences were found to be significantly higher in keratoconus eyes than in normal eyes by Li et al. (2012). This implied that an early diagnosis of disease might be facilitated by the use of epithelial mapping on those cases where the topography is normal. Epithelial thickness mapping was also shown by Rocha et al. (2022) to be abnormal in the normal appearing eyes, emphasizing the need for epithelial evaluation in the detection of subclinical keratoconus. The advantages of using AS-OCT are a number of: It is a very fast imaging technique, has superb repeatability and imaging is non-contact, leading to minimal patient discomfort.

High resolution imaging can also be utilized to evaluate corneal scars, stromal thinning and corneal changes following cross-linking. But alterations of the epithelium can occur in conjunction with other ocular surface conditions like contact lens warpage and dry eye disease. Thus, AS-OCT is typically used as an adjunctive diagnostic tool and not a primary diagnostic imaging method. Incorporation of tomography and biomechanical assessment, therefore, gives greater confidence in the diagnosis and increases the overall accuracy of diagnosis.

2.4.5 Artificial Intelligence in Keratoconus Diagnostics

Presently, artificial intelligence (AI) stands out as one of the most promising advancements in the field of ophthalmic diagnostics. These AI systems can process vast amounts of information

from various imaging techniques and uncover intricate patterns that might not be apparent to human interpretation. Machine learning and deep learning models have thus shown great promise in enhancing keratoconus screening and classification. The use of deep learning algorithms trained on Scheimpflug imaging data yielded high sensitivity and specificity for detection of early keratoconus as shown by Xie et al. (2020). The system was able to distinguish between normal corneas and subclinical ectasia with a high degree of success, indicating that AI-powered interpretation could improve the accuracy of diagnosis. Likewise, Yousefi et al. (2022) designed machine learning models that can be used for keratoconus severity classification based on tomographic parameters. Their results showed the benefits of AI-driven systems in terms of improving diagnostic consistency and decreasing the interobserver variability. When combined with tomography and biomechanical assessment and epithelial thickness mapping, multimodal AI models performed better than conventional diagnostic indices, as reported by Kuo et al. (2023).

These results confirm the hypothesis that a combination of tests is more effective than any single test alone, as keratoconus is a disease with multiple components that include structural, biomechanical and epithelial changes. AI systems can also enhance workflow efficiency by automating risk stratification and standardisation of interpretation in various clinical settings. Though satisfactory, the use of such algorithms poses issues of transparency, data quality and generalisability in ethnically varied populations.

The majority of AI research studies are retrospective and often use datasets from a single centre that can lead to overfitting and limit generalizability. Before widespread clinical implementation there is need for prospective multicentre validation studies. However, the future of keratoconus diagnosis and refractive surgery screening is trending toward multimodal analysis with the assistance of AI.

2.5 Research gap

The reviewed literature showed significant progress in the keratoconus diagnosis using tomography, biomechanical imaging, epithelial mapping, and artificial intelligence-based system. Yet there are significant knowledge deficiencies in the current body of knowledge. Previous studies have primarily assessed the diagnostic modalities one to one, but not across several technologies in the same clinical population. In practice, however, there are few data available on the relative effectiveness of topography, tomography, biomechanical assessment and AS-OCT. The majority of studies were retrospective, and generally took place in highly

controlled environments and contexts, which restricted the generalisability to routine optometric contexts. However, there are practical issues that have not been fully explored and these include the usability of the clinicians, accessibility, ease of use within the clinician's workflow and cost-effectiveness. Moreover, AI-powered diagnostic systems have been shown to have potential accuracy, but their validation in a wider clinical population remains limited. Issues about how it can be integrated into the routine clinical workflow are still not settled. Only a few studies have investigated the synergy of structural, biomechanical and epithelial parameters in a prospective study. In addition keratoconus diagnostic research typically lacks interrater reliability and clinician opinion on usability. The aim of the current study was to address these limitations by performing a prospective comparative assessment of corneal topography, tomography, biomechanical assessment and multimodal imaging, and assessing the clinical applicability and usability and the level of observer reliability.

2.6 Chapter summary

This chapter summarized the theoretical and empirical studies on early diagnosis of keratoconus and the efficacy of the available diagnostic technologies. While the review showed that corneal topography still has value in the diagnosis of manifest keratoconus, advanced tools like corneal tomography, biomechanical assessment technologies, AS-OCT epithelial mapping and artificial intelligence-assisted systems are more sensitive in detecting early and subclinical keratoconus. Theoretical aspects of corneal biomechanics and the mechanisms of ectasia progression helped illustrate the importance of multimodal diagnostic approaches, as structural weakening and changes in the posterior cornea may occur prior to the appearance of any anterior structural abnormalities. Empirical evidence also demonstrated that combining structural, biomechanical, and epithelial evaluation resulted in a greater level of accuracy, decreased observer variability, and improved disease monitoring. Nevertheless, there are critical knowledge gaps in prospective comparative evaluation, practical usability, workflow integration, and system validation in a variety of populations for AI-assisted systems. The gaps formed the basis for the current study which aims to compare the modern diagnosis methods of keratoconus and its usefulness in clinical practice.

CHAPTER THREE

RESEARCH METHODOLOGY

3.1 Introduction

In the present chapter the research methodology used in the study has been presented. It refers to the research design, the study population, sampling procedures, research instruments, data collection procedures, data analysis methods and ethical considerations used in the investigation. The chapter also provides the justification for the choice of methodological approaches and provides an explanation of some of the steps taken to secure the validity,

reliability and consistency of data collected. The method was designed according to the objectives of the study and the literature related to the diagnosis of keratoconus. The study was undertaken to compare the diagnostic performance of different imaging modalities in the diagnosis of early keratoconus, and a structured and standardised clinical approach was used. The chapter also outlines the process of selection of the participants, measurement of the measures, and their statistical analysis in the MS Excel software.

3.2 Research design

The study used a prospective cross-sectional analytical research design to assess and compare the diagnostic capabilities of various corneal imaging techniques in keratoconus detection. A cross-sectional study was deemed suitable as it allowed the assessment of the diagnostic accuracy among various groups of participants at one point in time. Given that the study was prospective, the data collection procedure adhered to a standardised format and strict protocol during the study (Setia, 2016).

The design enabled multiple diagnostic tools to be compared directly under similar clinical conditions, enhancing the consistency and validity of the results. This design has been widely adopted in studies on diagnostic accuracy because it allows the simultaneous evaluation of sensitivity, specificity, and predictive values of different diagnostic modalities. Comparative and correlational research design elements were also included in the study. The differences in diagnostic performance of topography, tomography, biomechanical assessment, and AS-OCT imaging were evaluated using comparative analysis. Correlational analysis was applied to find the relationships between diagnostic indices like BAD-D, CBI, and TBI. Steps were taken throughout the study to ensure reliability through the use of standardisation procedures. Examination sequence and imaging protocol were the same for all participants, and measurements were repeated to reduce random error. Multiple scans were obtained for each participant for each diagnostic modality to achieve replication, namely Tomey RT7000 Topography , Optovue iVue Tomography and Revo FC NX Multimodal. The design was adequate for exploratory comparative analysis; however, limitations were that participants were assessed at one time only, and thus, the disease process could not be evaluated over the long term. However, the design was suitable for the study.

3.3 Study population

Patients were selected from specialised eye clinics, specifically cornea and refractive surgery clinics, where both clinical and subclinical keratoconus cases were more likely to be identified.

There were three groups of participants: People who had been diagnosed with keratoconus, and people who had been diagnosed with keratoconus on first examination or topographic scans. Control participants without any evidence of corneal disease. This classification allowed for the evaluation of diagnostic instruments over the entire range of the disease, from normal corneas to early and advanced keratoconus. Inclusion of a keratoconus suspect group was especially significant since the primary aim of the study was the early detection stage, at which the level of diagnostic uncertainty is highest (Ambrósio et al., 2011). Both males and females were included in the age range targeted. The use of specialised clinics ensured that a good range of cases of different stages of keratoconus was recruited. The study population was chosen because these participants were able to offer clinically relevant data for comparing the efficacy of new diagnostic technologies in the clinical care of patients in the optometrist's and ophthalmologist's offices. Determine the sample size and sampling procedure. The study involved at least 30 participants and included about equal numbers amongst the three groups of participants. The sample size was found to be sufficient for an undergraduate exploratory comparative research study using multiple diagnostic modalities. Participants were recruited using a purposive sampling technique and met the criteria for the study. Purposive sampling was deemed appropriate as it is a study that would need patients who have a known diagnosis of keratoconus and those who were suspected to have keratoconus. The recruitment of the participants was made sequentially from the participating eye institutes during the data collection period. Those who met the inclusion criteria and who gave their consent were recruited into the study until the required sample size was reached. The size of the sample was relatively small, but the previous pilot and comparative studies that tested diagnostic technologies for keratoconus had applied comparable samples, especially when several imaging modalities were used (Vinciguera et al., 2020). It was recognised that a larger sample size would have yielded increased power and generalisability of results. But the number of samples for exploratory analysis and comparison of diagnostic indices was still sufficient.

3.4 Sample size and sampling procedure

A minimum sample size of 30 participants was included in the study, with approximately equal representation across the three participant groups. The sample size was considered appropriate for an undergraduate-level exploratory comparative study involving multiple diagnostic modalities.

A purposive sampling technique was used to recruit participants who met the study criteria. Purposive sampling was considered suitable because the study required participants with specific clinical characteristics, including confirmed keratoconus and suspected keratoconus cases.

Participants were recruited consecutively from participating eye clinics during the data collection period. Eligible participants who met the inclusion criteria and consented to participate were enrolled in the study until the desired sample size was achieved.

Although the sample size was relatively small, previous pilot and comparative studies investigating keratoconus diagnostic technologies had utilised similar sample sizes, particularly where multiple imaging modalities were involved (Vinciguerra et al., 2020).

It was acknowledged that a larger sample size would have improved statistical power and generalisability of findings. However, the selected sample size remained sufficient for exploratory analysis and comparison of diagnostic indices.

3.5 Inclusion criteria

The participants were included in the study if they had the following characteristics: Between the ages of 6 and 45 years old, identified as having keratoconus, suspected keratoconus, or healthy controls, had no history of ocular surgery, could give informed consent or assent if they were minors with the consent of their parents. The age range was chosen since keratoconus usually occurs and develops from adolescence to early adulthood. But, a recent study in Zimbabwe showed that the incidence of keratoconus was quite high in school children, which is why younger participants were included (Masiwa and Moodley, 2024). Ocular surgery can affect corneal shape and biomechanics, which may lead to confounding effects if participants had previously undergone an intervention. Confounding effects were minimised by excluding participants who had previous ocular surgery because it can alter corneal shape and biomechanics. The participants were also required to follow examination procedures and imaging requirements to ensure the accurate and reliable collection of data.

3.6 Exclusion criteria

Included were participants who had any of the following: Corneal Crosslinking is a procedure that has been performed previously. Corneal scarring/ dystrophies/ infection/ other corneal pathologies. No time lapse before contact lens wear. Failure to cooperate in imaging procedure(s). Patients who had undergone corneal cross-linking were excluded since it changes

the biomechanical properties of the cornea that can potentially influence the diagnosis. To minimize the potential for confounding factors that could complicate the interpretation of the imaging findings, individuals with other corneal diseases were excluded. The participants with soft contact lenses had to stop wearing the lenses for at least two weeks prior to examination, and rigid gas-permeable lens wearers had to stop wearing the rigid contacts for at least four weeks (Gomes et al., 2015). This reduced the temporary changes to the shape of the cornea resulting from wearing contacts. They were also excluded if they failed to maintain fixation or if they were unable to cooperate in the imaging procedures, because poor imaging quality could lessen the reliability of the measures.

3.7 Research instruments

During data collection, several research instruments and diagnostic devices were employed. The instruments chosen were relevant to the study goals, and they measure structural and biomechanical corneal parameters that are associated with keratoconus. Standardised Snellen charts were used to measure visual acuity. Refractive status was measured using objective and subjective refraction instruments, and irregular astigmatism was detected in keratoconus. Health of the anterior segment was evaluated using a slit lamp biomicroscope and retinoscopy, and clinical signs of keratoconus were noted, including corneal thinning, Fleischer's ring, and Vogt's striae.

Anterior corneal curvature patterns were assessed using corneal topography conducted with a Placido-disc-based topographer, Tomey RT7000. Anterior and posterior corneal elevation and pachymetry mapping were obtained with corneal tomography using a Scheimpflug imaging device , Optovue . Anterior Segment Optical Coherence Tomography (AS-OCT) was used to analyze epithelial thickness distribution and determine remodelling patterns of the epithelium in early keratoconus (Reinstein et al., 2021). The Revo NX FC device was used. Biomechanical assessment was performed with the Corvis ST device, where possible. Biomechanical assessment equipment was made available to the participants by collaborating with Dr Bawa in South Africa for those willing to travel to be assessed. For each imaging modality, at least two scans were collected per participant, and only scans qualifying for the manufacturer's recommended QA were analysed, to increase reliability.

3.8 Data collection procedures

Data collection was based on a standardised clinical protocol that was used to ensure consistency and reliability in data collection across all participants. Before the examination,

appointments were set up with eligible participants via participating clinics. Participants were given a detailed written description of the procedures of the study upon arrival and were required to sign an informed consent form. Demographic data and clinical history was then collected on a structured data collection form. Visual acuity was determined for each participant, followed by objective and subjective refraction. A slit lamp exam and retinoscopy was then performed to examine the health of the anterior segment and to look for clinical features of keratoconus.

The corneal imaging procedures were then carried out in a standardised sequence. Corneal topography was performed first and then corneal tomography and AS-OCT imaging, and, if available, a biomechanical assessment. Repeated scans were taken to increase the reliability of measurements for each imaging modality. Was repeated immediately if the image quality was poor or not acceptable as per the manufacturer's guidelines. All data collected were recorded systematically and securely stored for further analysis.

3.9 Data analysis

Data was analysed in Microsoft Excel. Data collected were entered into computer spreadsheet programs, cleaned, coded, tabulated, and graphed for interpretation. Demographic and clinical characteristics of participants were summarized using descriptive statistics such as means, standard deviations, frequencies, and percentages. Sensitivity, specificity, positive predictive value (PPV), and negative predictive value (NPV) were used to assess the diagnostic performance of each imaging modality.

The receiver operating characteristic (ROC) curve analysis was also performed for comparison of the diagnostic accuracy of modalities. The Area Under the Curve (AUC) was used as an indicator of overall diagnostic performance (Zweig and Campbell, 1993). Pearson or Spearman correlation coefficient was used for the correlation analysis, depending on the distribution of the data. This analysis was used to assess correlations among diagnostic indices from various modalities, including BAD-D, CBI, and TBI.

Comparative analysis was performed to see if the multimodal diagnostic methods showed better diagnostic performance than single modality evaluation. Results presented in tables, charts, and graphical summaries for enhanced interpretation and comparison.

3.10 Validity and reliability

Validity and reliability of the study findings were ensured by several measures. All participants were examined using standardised procedures to reduce procedural variability. Before data collection began, all imaging devices were calibrated as per the manufacturer's instructions. Several scans were obtained per participant, and only high-quality scans were used for analysis. More than one observer interpreted imaging findings for which interrater reliability checks were performed.

This aided in the harmonisation of the interpretation of diagnostics and coding. Multiple diagnostic modalities further enhanced construct validity by allowing for comparisons and verification of results between the modalities.

3.11 Ethical considerations

Ethical clearance for the study was received from the appropriate institutional ethics committee before data collection. Written informed consent was obtained from all participants after a detailed explanation of the purpose, procedures, benefits, and potential risks of the study was given. Parental/guardian consent and consent of the participant were obtained for those participants under 18 years of age. All data gathered was anonymised and electronic records held in password-protected systems, with only the research team having access. The study has been conducted in accordance with the ethical principles of the Declaration of Helsinki 2013 – respect for persons, beneficence, non-maleficence, and voluntary participation. Participants were told that they were free to join the study and that they could drop out of the study without any penalties or adverse consequences.

3.12 Chapter summary

In this chapter, the research methodology employed in this study was described. The study was designed as a prospective cross-sectional analytical study, comparing modalities for early detection of keratoconus. Clearly explained the study population, sampling procedures, instruments, inclusion and exclusion criteria and data collection procedures. The chapter also included the methodology on how the data have been analysed in this study by Microsoft Excel and the steps taken for validity, reliability and ethical considerations. The methodology offered a framework to assess the diagnostic value of corneal topography, tomography, biomechanical assessment and multimodal imaging techniques. The results and findings from the study will be presented in the next chapter.

CHAPTER FOUR

RESULTS AND DATA ANALYSIS

4.1 Introduction

The results of this comparative study of corneal topography, corneal tomography, corneal biomechanical assessment and multimodal imaging techniques for early detection of keratoconus are presented. The results are reported in the light of the study objectives and research questions as set out in Chapter One. Thirty participants were recruited and completed the study. Each participant had their both eyes evaluated, which gave 60 eyes of the

participants. The chapter gives an overview of the demographics of the subjects, the diagnostic data from each of the imaging modalities and a comparison of the diagnostic capabilities. Over in addition, clinician usability assessments and patient satisfaction responses, including comfort, privacy, duration of testing, image clarity, and ease of understanding instructions, are also reported. Data were summarised using descriptive statistics (frequencies, percentages, means, and standard deviations). If applicable, comparative statistical analyses were performed to assess the differences between imaging modalities and to evaluate the efficacy of multimodal imaging in the detection of early keratoconus. The findings are reported in tables and figures to aid in the interpretation and discussion.

4.2 Response rate

4.2 Response Rate The percentage of those who completed a study divided by the number of those recruited to complete the study is the response rate (Polit & Beck, 2021). Response rates are crucial as they reduce non-response bias and enhance the dependability and validity of the study results. All 30 participants were recruited and completed the diagnostic assessments and questionnaires in the present study. Thus, data was collected from all participants and from both eyes of each participant, for a total of 60 eyes analyzed.

Table 4.1: Participant Response Rate

Variable	Frequency (n)	Percentage (%)
Participants approached/recruited	30	100
Participants who completed the study	30	100
Participants who did not complete the study	0	0
Total eyes examined	60	100

Response Rate Calculation

$$\text{Response rate} = \frac{\text{Number of participants who completed the study}}{\text{Number of participants approached}} \times 100$$

$$= \frac{30}{30} \times 100 = 100\%$$

Complete data was collected as 100% of respondents participated in the study, showing high compliance of participants. As per methodological research, it is believed that the response rate of more than 80% is considered good for minimizing response bias and representativeness of

study findings (Polit & Beck, 2021; Creswell & Creswell, 2018). The return of the questionnaires was thus regarded as very satisfactory, and this gave a good data basis for further analysis.

4.3 Baseline characteristics of the study population

Thirty participants were included in the study, comprising 17 normal subjects (56.7%), 5 keratoconus suspects (16.7%), and 8 subjects diagnosed with keratoconus (26.7%). Mean corneal thickness decreased progressively from 489.97 ± 40.99 µm in normal eyes to 409.00 ± 49.66 µm in suspect keratoconus and 353.81 ± 81.68 µm in keratoconus.

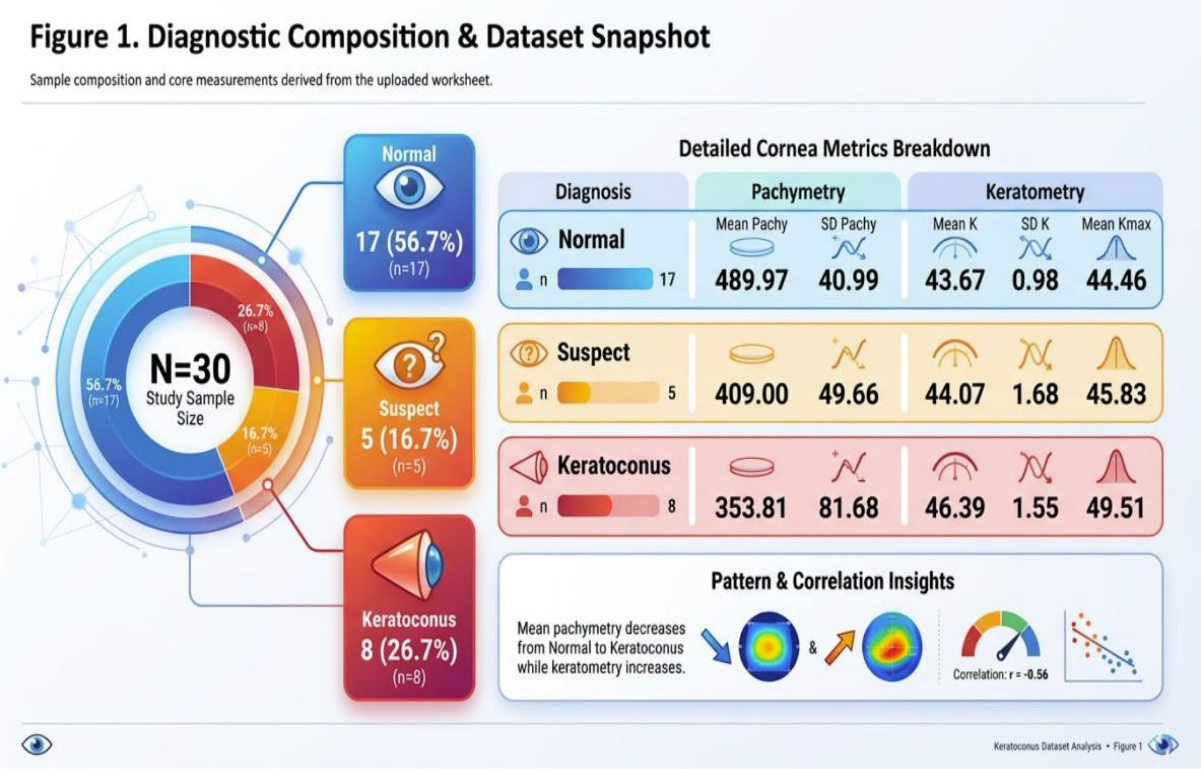

Fig 4.1 Baseline characteristics of the study population

Conversely, mean keratometry increased from 43.67 ± 0.98 D in normal eyes to 46.39 ± 1.55 D in keratoconus. Maximum keratometry values showed a similar trend, increasing from 44.46 D in normal subjects to 49.51 D in keratoconus. A moderate negative correlation (r = –0.56) was observed between pachymetry and keratometry, indicating that thinner corneas were associated with steeper corneal curvature. These findings support the established structural changes associated with progressive keratoconus and demonstrate the diagnostic value of combined pachymetry and keratometry assessment.

4.4 Corneal thickness distribution by diagnostic category

Figure 4.2 presents a comparative analysis of corneal pachymetry measurements across the three diagnostic groups: Normal, Keratoconus Suspect, and Keratoconus. The box-and-whisker plots illustrate the distribution of the thinnest corneal point measurements for 60 eyes, while individual data points provide insight into the variability and overlap between groups. Corneal thickness is a critical structural parameter in keratoconus diagnosis because stromal thinning is one of the earliest and most characteristic manifestations of corneal ectasia.

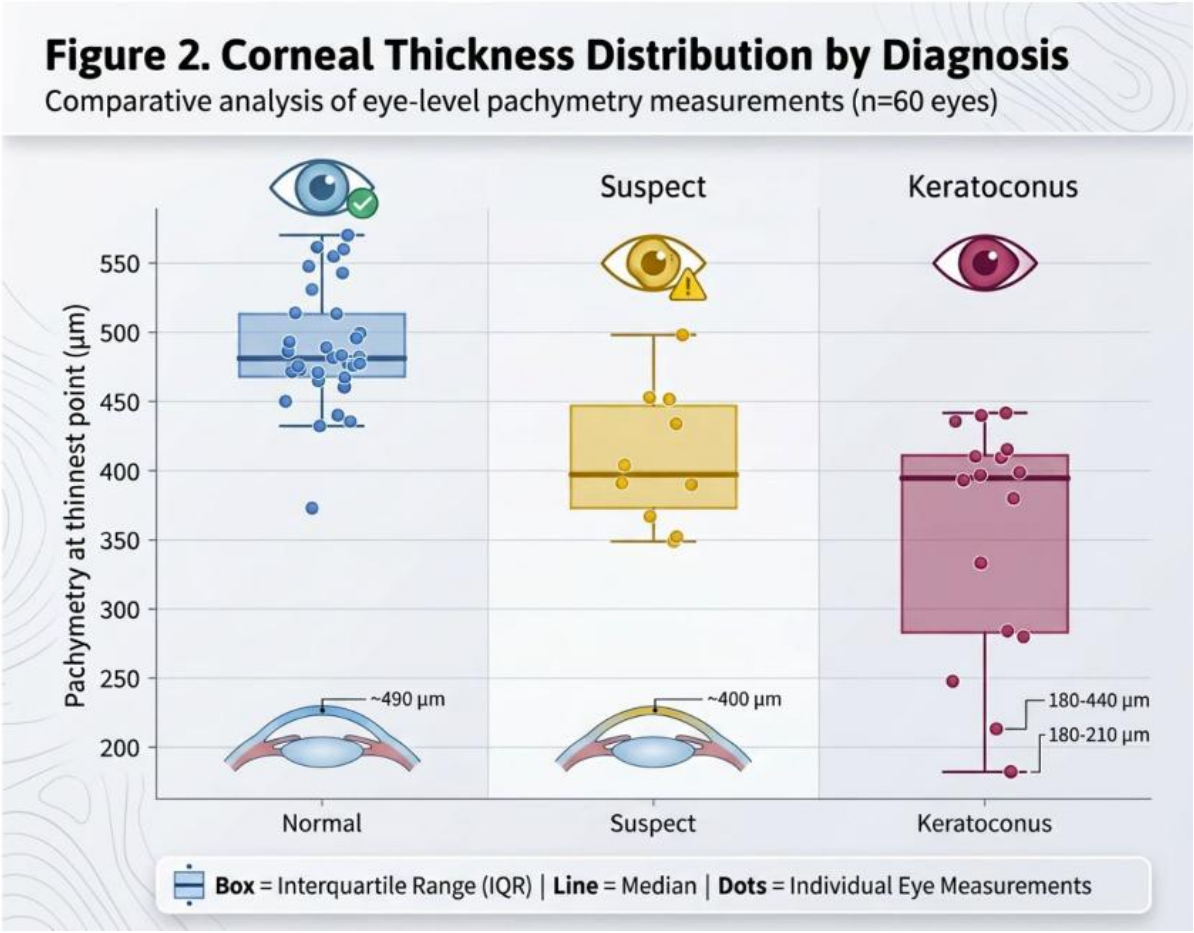

Fig 4.2 Corneal thickness distribution by diagnostic category

The pachymetry measurement is the thinnest in the Normal group, which has a median corneal thickness of about 480–to-490 µm. The majority of the measurements fall within a fairly small interquartile range, suggesting that there is not much variation and the corneas of healthy individuals are quite structurally consistent. Most of the eyes were between about 460 µm and 520 µm, with a few exceeding these limits. This is a relatively small distribution, indicating the normal physiological stability of the corneal stroma and suggesting a homogenous population of cells, with an intact cornea architecture. The small range of measurement also suggests that

in healthy individuals, the pachymetry measurements are relatively reproducible and suggests low structural irregularity. The Keratoconus Suspect group shows a progressive thinning of the cornea in comparison to the Normal group. The median pachymetry is reduced to about 400 μm, over 200 μm less of corneal thickness.

In addition, the interquartile range is wider than the one found in the Normal group, suggesting more variation within the suspect group. This may be a result of the variable nature of the ectatic disease at an early stage, some eyes having mild structural changes, and others being more severely affected with thinning. Some overlap between groups exists between the Normal and the Suspect groups and between the Suspect and the Keratoconus groups, reflecting the uncertainty of diagnosis that may occur in the early stages of the disease. This overlap is clinically important as it demonstrates the reason why early keratoconus often goes undiagnosed using a single diagnostic parameter.

The most distinctive pachymetry abnormalities are seen in the Keratoconus group. The median thickness is in the range of 390–400 μm, but the distribution is significantly broader in the present group than either of the other two groups. They range from very thin corneas (as near to 180-210 μm) to more than 440 μm. This large spectrum reflects the different degrees of keratoconus within the study population, as well as the progressive nature of keratoconus. Some of the eyes may be in the early stages of keratoconus, and others are in advanced stages with very deep stromal thinning. There is direct evidence of advanced biomechanical compromise and a great amount of structural deterioration through the presence of extremely low pachymetry values. It is important to note that in the above groups (illustrated in Figure 4.2), corneal thickness decreases as the degree of diagnosis increases. There is an apparent progression from Normal to Suspect eyes and then to Keratoconus eyes. This progressive nature is consistent with the current concept of keratoconus being a continuum, rather than a binary disease state.

The weakening of the structure seems to be a gradual process, and the stage with suspect eyes falls between healthy corneas and clinically manifest keratoconus. This is consistent with earlier work showing that pachymetry changes frequently precede definite topographic or clinical evidence of disease. Pachymetry, therefore, could be important as an early biomarker of ectatic change. Although there appears to be a trend, there is significant overlap between the suspect and keratoconus group. Several eyes with keratoconus have similar pachymetry readings to suspected keratoconus eyes, and some suspected eyes have values that are very

close to the lower limits of the normal range. This overlap suggests this is one of the shortcomings of pachymetry as a pure diagnostic tool. It is common to see people with keratoconus who have thinning corneas, but not all thinning corneas are necessarily keratoconus. In some, biomechanical instability or posterior elevation abnormalities may occur prior to significant thinning and in others, corneas may be naturally thin without signs of ectactic disease. Thus, there is the possibility of false-positive and false-negative classifications when only relying on pachymetry. This is also significant as an increasing variation from the Normal to the Keratoconus groups. The thickness measures of healthy corneas are relatively uniform, whereas in keratoconus corneas, there are significant differences. The increase in the prevalence of KCs is due to the multifactorial nature and evolution of the disease. This is because of variations in disease duration, genetic susceptibility, biomechanical susceptibility, environmental factors and different rates of disease progression. The presence of both moderately thin and severely thinned corneas even in the keratoconus group further highlights the necessity of disease staging and clinical assessment for each patient. The results are very consistent with current knowledge on keratoconus from a pathophysiological point of view. This results in localized thinning of the cornea due to progressive degradation of the stromal collagen fibres, an increase in proteolytic activity, oxidative stress, and a decrease in biomechanical integrity. The cornea will progressively lose its strength, and will become prone to the effects of normal intraocular pressure, which lead to ectatic protrusion and distortion of the cornea and hence a reduction in visual function. The significant decrease in pachymetry seen in keratoconus eyes in this study therefore supports these underlying disease mechanisms. Importantly, the results presented in Figure 4.2 strongly support Objective 3, which aimed to assess whether a combined multimodal approach to diagnosis was more accurate than a single modality approach. The pachymetry is able to differentiate between the diagnostic groups, but some overlap between the eyes in the suspect and keratoconus groups shows that the thickness value is not enough for the diagnosis. Furthermore, the unachievable complete separation of all diagnostic categories underlines the need for using other parameters like corneal topography, tomography, biomechanical assessment, epithelial thickness mapping, and artificial intelligence-based analyses.

The complementary modalities are able to identify structural, morphological, and biomechanical abnormalities that may not be identified by the pachymetry evaluation alone. The results thus indicate that the measurement of corneal thickness should be considered a part of a multifaceted diagnostic approach, not a singular diagnostic criterion. Although pachymetry

is important for assessing the integrity of the stroma and severity of keratoconus, combining several diagnostic parameters is essential to detecting early and subclinical keratoconus. The findings of this figure support the hypothesis that multimodal assessment is likely to have better diagnostic sensitivity and lower misclassification rates and will aid earlier intervention with treatments like corneal collagen cross-linking.

4.5 Comparative analysis of group means and variability across diagnostic categories

Comparative analysis of three important corneal parameters: Pachymetry, Mean keratometry (Mean K), and Maximum keratometry (Kmax) is done in the Normal, Suspect keratoconus, and Keratoconus (KCN) groups as shown in Figure 4.3. The results show a consistent and clinically significant decrease in corneal thickness and an increase in corneal curvature with the progression of the disease, from normal corneas to established keratoconus.

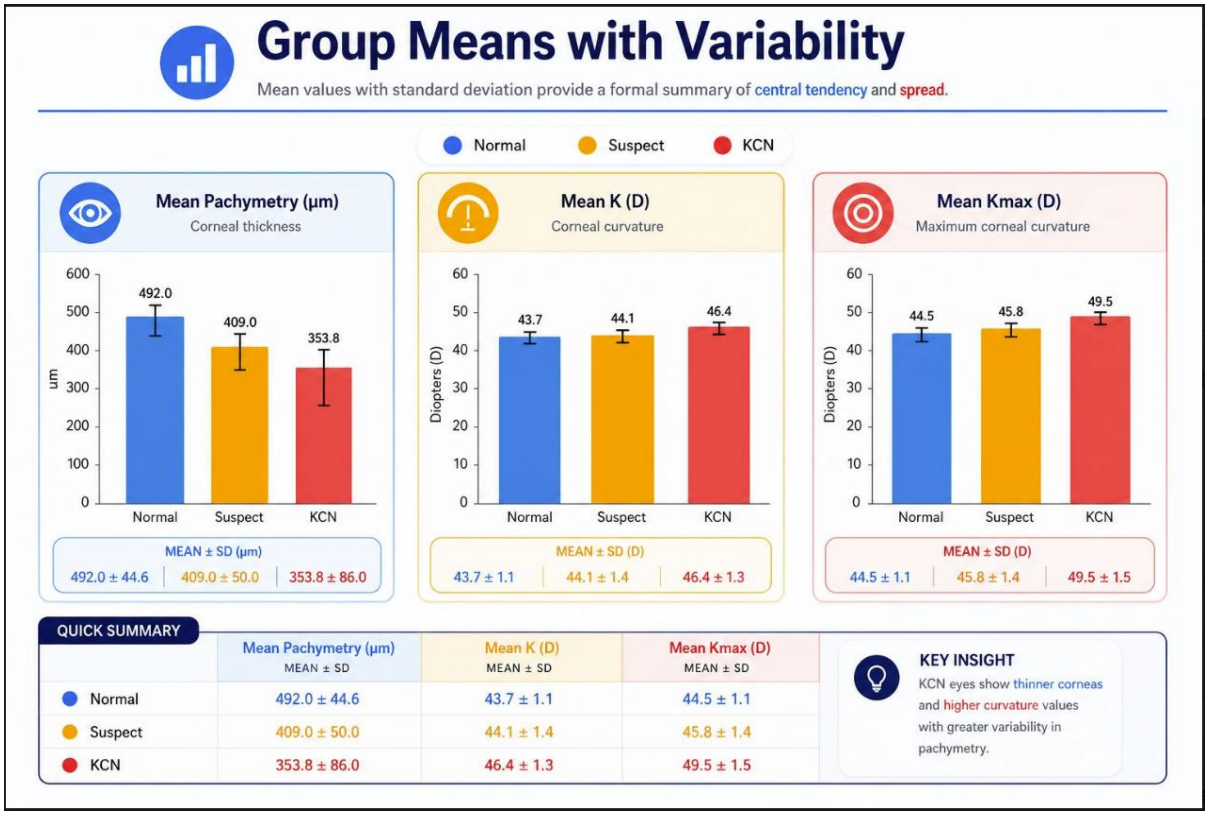

Fig 4.3 Comparative analysis of group means and variability across diagnostic categories

Pachymetry analysis

Significant differences were found to be present between the three diagnostic groups as seen in the mean pachymetry values. The mean pachymetry of the normal eye was 492.0 ± 44.6 µm

followed by the Suspect eye with mean pachymetry of 409.0 ± 50.0 μm and the KCN eye with the lowest mean pachymetry of 353.8 ± 86.0 μm.

The decrease in corneal thickness between Normal and Suspect groups is ~ 83 μm and from Suspect to KCN is ~ 55 μm. Overall, the thickness of the cornea was found to be about 138 μm thinner between Normal and KCN eyes, which is close to a 28% decrease.

This progressive thinning is one of the characteristic structural abnormalities of keratoconus, and is a manifestation of the underlying stromal tissue loss that is part of the keratoconus process. Histopathological changes such as the disorganisation of collagen lamellae, keratocyte apoptosis and increased enzymatic degradation of corneal stromal tissue have been shown to lead to corneal thinning and biomechanical weakening (Gomes et al., 2015).

The point to be noted is that the standard deviation is much higher in the KCN group than in the Normal group and Suspect group (86.0 μm vs 44.6 μm and 50.0 μm respectively). This variation was larger than expected indicating significant differences in the severity of keratoconus eyes. Some of the eyes might be fairly early ectasia eyes while others may be more advanced with thinning of the stromal tissue. The wide range of values thus gives an idea of the progressive and highly variable nature of keratoconus.

The mean pachymetry of the three groups differs significantly, indicating that measurement of corneal thickness is a good discriminator between normal and diseased eyes. Significant thinning of Suspect eyes compared with Normal eyes suggests that pachymetry changes are relatively early events in the disease process, consistent with previous reports of abnormal pachymetry progression preceding obvious anterior corneal steepening (de Sanctis et al., 2008).

Analysis of mean keratometry (mean K)

The Mean K results progress with an increase in average K values throughout the diagnostic range. The mean keratometry value in normal eyes was 43.7 ± 1.1 D, in Suspect eyes was 44.1 ± 1.4 D and in KCN eyes was 46.4 ± 1.3 D. The difference in degrees between Normal and Suspect eyes may seem small (0.4 D), but it is important as it represents the first signs of corneal steepening. The increase is significantly larger in advanced keratoconus, in which Mean K increases by some 2.7 D compared to the Normal eyes.

Limited variability is reflected in the relatively small standard deviations in all groups, which means that Mean K is a stable measure. This indicates that keratometry yields reproducible

corneal curvature values and could be a reliable tool to assess disease activity once structural modifications have occurred.

But the fact that there is overlap between Normal and Suspect highlights an important limitation of keratometry. In early keratoconus, there are changes in the posterior corneal surface elevation and biomechanical weakening that precede significant anterior surface flattening. Thus keratometry may not be a sensitive enough test to detect subclinical disease (Ambrosio et al., 2011).

This observation serves as the rationale for multimodal imaging approaches. Mean K is a good tool for identifying moderate and advanced keratoconus, but may not detect the earliest signs of keratoconus before measurable changes in the curvature.

Kmax analysis is used to determine the maximum keratometry.

This is particularly true of Kmax, which showed the largest difference between the three groups and seems to offer the greatest distance between diagnostic groups.

The following means of Kmax values were obtained:

Normal: 44.5 ± 1.1 D

Suspect: 45.8 ± 1.4 D

KCN: 49.5 ± 1.5 D

The Kmax in KCN eyes increased by about 5.0 D when compared with those of Normal eyes. This degree of change is significantly higher than the magnitude of change seen with Mean K, and demonstrates the focal nature of corneal protrusion in keratoconus.

Kmax is the steepest corneal point, as Mean K is the average of the curvature around the central cornea. Kmax is especially sensitive to the progression of keratoconus because the disease is characterised by a localized ectatic protrusion instead of the uniform corneal steepening.

The high number in the KCN group indicates that the development of the focal cones increases with the progress of the disease. This result confirms previous research showing that the Kmax is one of the most useful tomographic parameters for assessing the severity of keratoconus and monitoring progression (Belin & Duncan, 2016).

The Suspect group showed a slight increase in Mean K, but Kmax showed a more significant increase, implying that there may be a progression of focal changes which can occur before the

overall steepening of the cornea is seen. This further confirms the utility of Kmax as an early sign of ectatic disease.

A precise estimate of corneal curvature is important for determining pachymetry.Correct estimation of corneal curvature is essential to measure pachymetry.

The most significant result obtained from Figure X is that there is an inverse relationship between the corneal curvature and pachymetry.

As the thickness of the cornea went down:

Mean K increased.

Kmax increased.

Measurement variability increased.

This pattern is analogous to the basic biomechanical mechanism of keratoconus. The thinning of the stromal tissue results in corneal softness and decreased support of intraocular pressure. As a result, the cornea bulges forwards, causing the local steepening and increased curvature (Vinciguerra et al., 2016).

These data strongly suggest that thinning of the cornea and steepening of the cornea are correlated expressions of the same pathological process.

Diagnostic implications

The results indicate different contribution of the three parameters to keratoconus detection:

Parameter Clinical utility

Pachymetry Good indicator of early ectatic changes and structural weakening

Mean K - corneal steepness (useful for general corneal steepening and progression)

Kmax Most sensitive indicator of focal ectatic protrusion and disease severity

While all three parameters were useful for distinguishing between Suspect and KCN eyes, they seemed to differ in their discriminatory value, with Kmax being the greatest.All three parameters were useful in distinguishing between Suspect and KCN eyes, but were not equal in their discriminatory value, with Kmax being the greatest. The value of Mean K is similar, but more overlap between Normal and Suspect groups.

These results corroborate the existing data indicating that there is no single parameter that is adequate for the best possible diagnosis. Instead, a combination of pachymetry, topographic and tomographic data offer a more thorough evaluation of corneal health and detect early and subclinical keratoconus (Ambrosio et al., 2011; Reinstein et al., 2019).

The results show a clear and progressive eye transition from Normal to Suspect to Keratoconus eyes with the following characteristics:

Progressive corneal thinning (492.0 μm → 409.0 μm → 353.8 μm).

Increasing in the mean corneal curvature (43.7 D - 44.1 D - 46.4 D).

Marked increase in maximum corneal curvature (44.5 D → 45.8 D → 49.5 D).

Greater variation in pachymetry measurements is indicative of greater disease variability.

Inverse correlation between corneal thickness and corneal curvature in accordance with the biomechanical progression model of keratoconus.

Taken together, these results support the study hypothesis that structural and curvature-based parameters vary systematically with disease severity and multimodal evaluation provides better diagnostic information than any single parameter.

The distribution of keratometry by diagnostic category is shown in the following table, which represents eye-level analysis (n = 60 eyes).

The keratometry distribution shown in Figure X is a statistically and clinically significant distribution that is typical of the natural course of keratoconus. The progressive keratometry steepening observed in the Normal group, the Suspect group and the Keratoconus group, is a hallmark of ectatic corneal disease (Rabinowitz, 1998).

One interesting finding is that the distribution of keratometry values in the Normal group is not as large as in the other groups. The interquartile range (IQR) is narrow and there is little variability, indicating a fairly stable curvature profile for healthy corneas. This is logical because, during physiological intraocular pressure (IOP), the biomechanics and architecture of the cornea are normal and maintain a normal shape (Gomes et al., 2015). The median value of ~43.8 D is within the accepted normal range reported in the literature (42.0 D - 44.5 D) (Klyce, 2009).

4.6 Keratometry distribution by diagnostic category (eye-level analysis, n = 60 eyes)

The keratometry distribution presented in Figure 4.4 demonstrates a statistically and clinically meaningful pattern consistent with the natural progression of keratoconus. The gradual increase in mean keratometry values from the Normal group through the Suspect group to the Keratoconus group reflects the progressive corneal steepening that characterises ectatic corneal disease (Rabinowitz, 1998).

A notable observation is the relatively compact distribution of keratometry values within the Normal group. The narrow interquartile range (IQR) and limited variability suggest that healthy corneas maintain a relatively stable curvature profile. This finding is expected, as normal corneal biomechanics and stromal architecture preserve corneal shape under physiological intraocular pressure (Gomes et al., 2015). The median value of approximately 43.8 D falls within the accepted normal range reported in the literature, generally between 42.0 D and 44.5 D (Klyce, 2009).

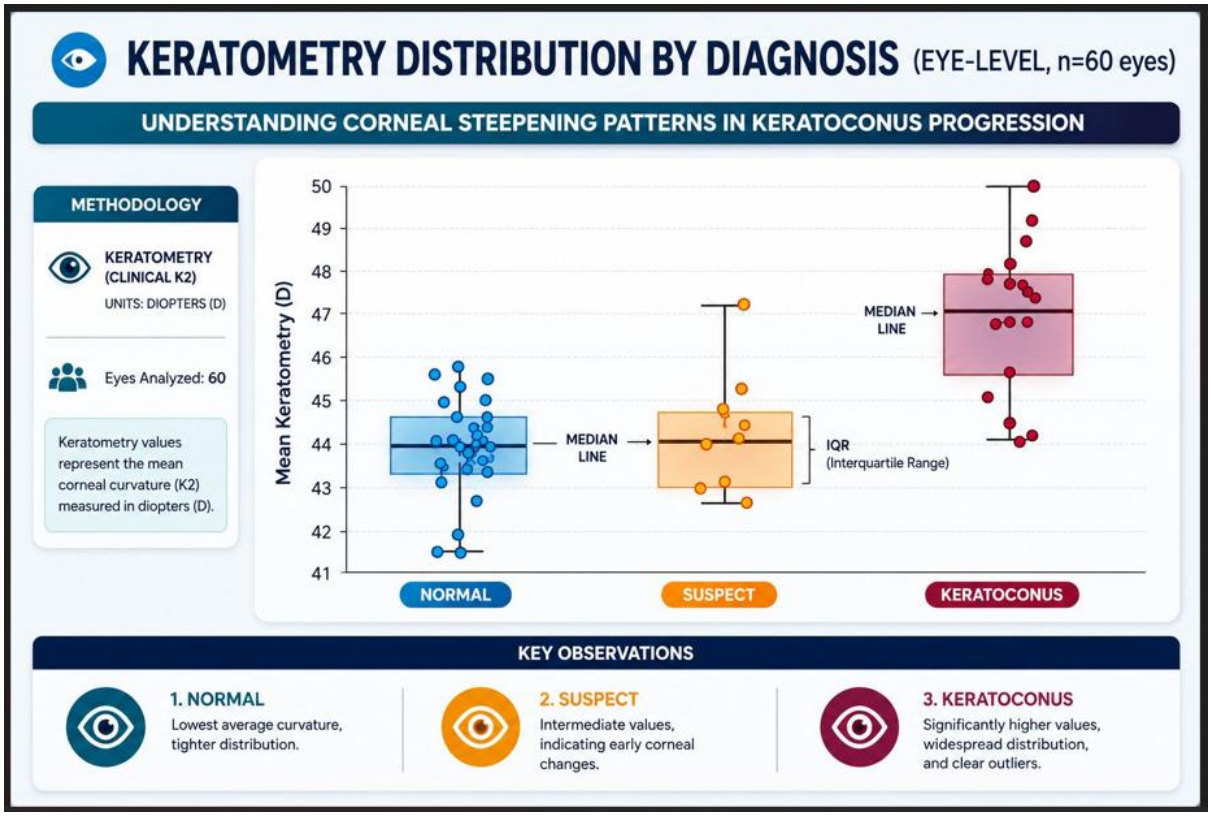

Fig 4.4 Keratometry distribution by diagnostic category

The Suspect keratoconus group has a minor, but significant increase in keratometry readings and in variability. This greater distribution is of special significance as it illustrates the variability of early ectatic disease. Some suspect eyes fall within a significant range of

keratometry values of the Normal group and others have values close to those found in keratoconus. An early stromal/bio-mechanical change occurs before there is significant steepening of the anterior cornea which is measurable by keratometry (Ambrosio et al., 2011), hence the keratometry-based diagnosis has one of its main limitations. Thus, the use of keratometry criteria alone might result in underdiagnosis of subclinical keratoconus.

The median keratometry value for the Keratoconus group is approximately 47.0D and the range of observations is the greatest. The high IQR shows that there is significant variation in the severity of the disease in affected eyes. The steepening varies from mild to severe, ranging up to 50.0 D in some eyes, indicating a high level of corneal protrusion. This greater variability is part of the nature of keratoconus as it is a highly personalised disease and affected by a variety of factors including the patient's genetic, environmental, eye rubbing and corneal biomechanical characteristics (Galvis et al., 2015).

It is clinically important that there are multiple high value observations included in the Keratoconus group. These values are typical of eyes that have a significant amount of corneal steepening and are typical of advanced changes in the cornea. Previous studies showed that keratometry values of 47.0 D or greater are good indicators of clinically manifest keratoconus and the severity of the disease (Rabinowitz, 1998). These extreme values further confirm the diagnostic value of keratometry for diagnosis of established disease.

An interesting aspect of the distribution is that there is an overlap between the Normal and Suspect groups. There is a progressive increase of median values, however, the separation of these categories is not complete, indicating that keratometry may not be sensitive enough to detect early keratoconus. The aforementioned observation is consistent with several studies reporting that posterior corneal elevation abnormalities, pachymetry progression changes, epithelial remodelling, and biomechanical weakening often pre-dated anterior corneal steepening that was detected by an increase in the refractive power of the cornea (de Sanctis et al., 2008; Reinstein et al., 2019; Vinciguerra et al., 2016). Hence there are some eyes that, while being normal by keratometry, already show early signs of ectasia by tomography or biomechanical measures.

The results lend some degree of support to the study hypothesis that multimodal assessments are likely to be more powerful than single-modality assessments from a diagnostic point of view. Therefore, keratometry is a useful tool for finding advanced disease, but is not sufficient on its own to distinguish Normal and Suspect eyes, highlighting the need for complementing

diagnostic technologies. The analysis of the Belin–Ambrósio Deviation Index (BAD-D), the Corvis Biomechanical Index (CBI) and the Tomographic Biomechanical Index (TBI), are examples of modern tomographic indices that have demonstrated their increased sensitivity in detecting subclinical keratoconus, when abnormal structures can be detected before significant corneal steepening occurs (Ambrosio et al., 2011; Vinciguera et al., 2016).

The overall results show a good dose-response curve relationship between keratometry and disease severity. The median keratometry and the variability values increase with progression from Normal to Suspect to Keratoconus. This is a typical progression of keratoconus and is representative of how this disease pathology progresses, establishing that corneal steepening is an important marker of keratoconus. The overlap found amongst the diagnostic categories, however, does highlight the potential of keratometry being a non-comprehensive screening tool for keratoconus, and has led to a strong argument for the use of tomograms, biomechanical imaging, and other advanced diagnostic tools in routine clinical practice to facilitate early detection of keratoconus.

4.7 Relationship between corneal thickness and corneal curvature

The correlation between the mean corneal pachymetry (corneal thickness) and mean keratometry (corneal curvature) in the study population (N = 30) is shown in figure 4.5. All the data points are coloured according to the diagnostic classification (Normal, KS, KC) and each point is a single participant. To assess the association between these two clinically important parameters, a linear regression line with a 95% confidence interval is shown on the scatterplot.

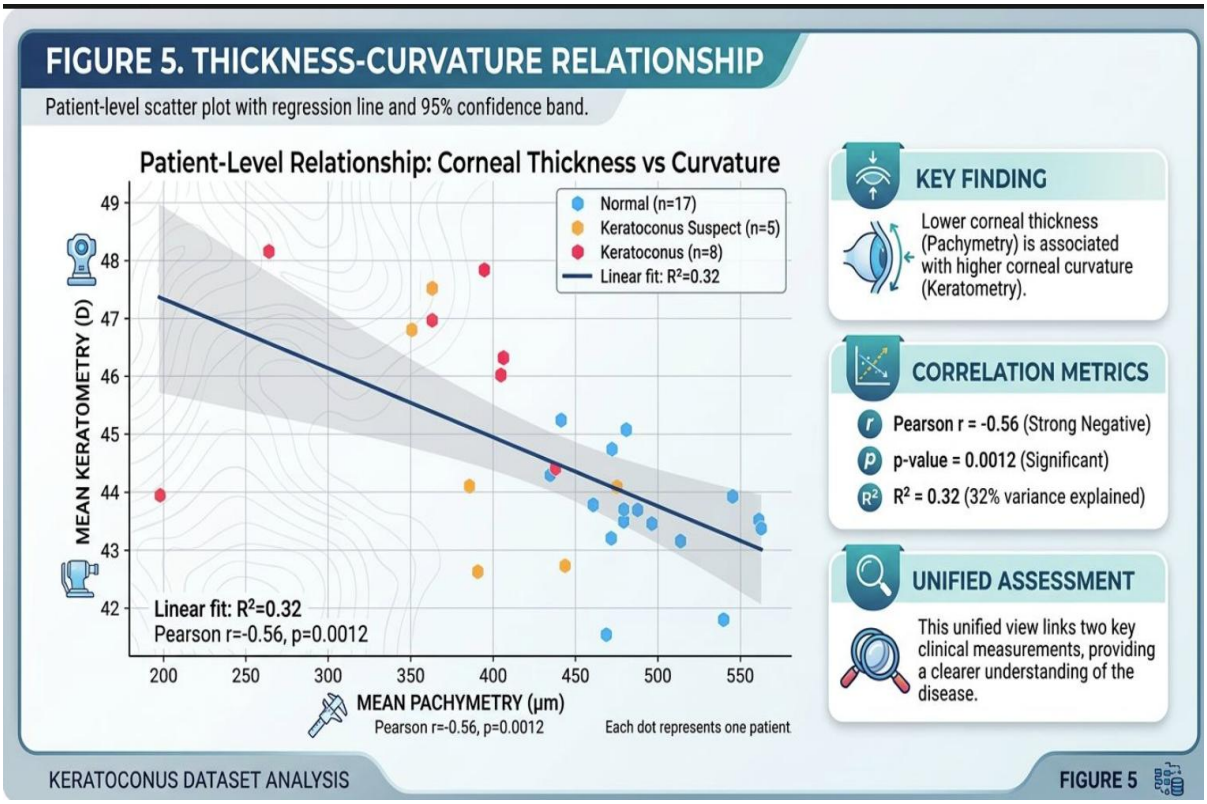

Fig 4.5 Relationship between corneal thickness and corneal curvature

The mean corneal pachymetry vs the mean keratometry in the 30 study subjects is shown in figure 4.5. From the scatter plot, it is evident that there is a general downward trend showing that the thicker the cornea, the flatter is the curvature. There is an inverse relationship because the regression line has a negative slope and the Pearson correlation coefficient is r = -0.56 with a statistically significant p-value of 0.0012. These results indicate that thinner corneas have steeper curvature values in line with the known pathobiology of keratoconus. The keratometry values will increase as the cornea gradually moves forward and flattens, losing the biomechanical stability of its cornea.

Upon scrutiny of the scatter plot, there is apparent clustering in terms of diagnostic classification. The distribution of participants can be broadly grouped as normal, with participants mainly in the higher pachymetry range and lower keratometry range, indicating that their corneas are in a healthy state, with the appropriate structure and curvature. The group of participants who were diagnosed with keratoconus, however, tend to be grouped together in the lower end of pachymetry and higher end of keratometry values, which is the characteristic feature of corneal ectasia.

The suspect keratoconus group is located between these extremes. This transition distribution is especially relevant as it represents the disease progression. Keratoconus is not a discrete disease, but rather goes through a continuum from normal corneas to the subclinical stage and then to manifest keratoconus. The overlap of the cases seen in the suspect and keratoconus group suggests that the diagnosis of keratoconus in early stages is difficult based on individual parameters.

The coefficient of determination ($R^2 = 0.32$) suggests that only 32% of the variation in the keratometry values can be attributed to corneal thickness. This is a significant share of the variation, but also illustrates that there is a small proportion of the variation (just under 68%) governed by other factors that are not recorded by pachymetry measurements. Such factors could be posterior corneal elevation, corneal biomechanical changes, epithelial remodelling, stromal collagen organisation, genetic factors, and environmental risk factors like chronic rubbing of the eye. As such, while corneal thickness can be a useful information to determine disease progression, it is not sufficient to determine the severity or risk of keratoconus on its own.

The results confirm the multifactorial character of keratoconus from a clinical viewpoint, and also illustrate the drawbacks of using a single diagnostic test to measure the disease. While the thinner the cornea, the steeper the corneal curvature, some participants have deviations from the overall trend. Certain eyes with relatively normal pachymetry will have increased keratometry values, while certain eyes with thin corneas won't show a corresponding increase in keratometry. This makes it likely that structural thinning and corneal steepening do not always occur together and that early changes in the cornea may even precede significant changes in the conventional measures. This variability emphasizes the importance of thorough assessment methods which can identify early signs and symptoms of disease before visual changes are obvious.

The results in figure 5 directly address Objective 3 of the study, which was to assess if a multimodal diagnostic approach (combined) offers better diagnostic accuracy than a single-modality approach. A moderate correlation between pachymetry and keratometry was noted, showing that these are not interchangeable and are related but not equal. Both measurements are not totally responsible for the clinical picture of keratoconus. Some eyes with early curvature abnormalities might be missed if it were just on the thickness of the cornea. Likewise, using keratometry alone may not be able to detect early stromal thinning or biomechanical

weakness before it results in significant steepening. The fact that the regression model has only limited explanatory power makes it highly likely that the disease is of complex nature, and that a single diagnostic parameter will not suffice to fully describe it.

Moreover, there were some commonalities between the two groups, suspect and keratoconus, which are useful in demonstrating the benefit of multimodal imaging. The presence of misclassification of each diagnostic group by only one of the two variables, pachymetry or keratometry, indicates that more diagnostic information is needed to increase classification accuracy. Advanced modalities like Scheimpflug tomography, biomechanical analysis with Corvis ST, epithelial thickness mapping with AS-OCT and artificial intelligence assisted analysis, may provide complementary information that could serve to identify disease at an earlier stage. Clinicians have the potential to gain a more comprehensive understanding of corneal health than any single modality can, by combining structural, topographical, and tomographic data with biomechanical data.

Overall, the findings show a relationship between corneal thinning and corneal steepening, which are both aspects of keratoconus progression but not the entirety of the disease process. The results of this study are statistically significant and provide evidence for the clinical importance of both pachymetry and keratometry as diagnostic markers. The moderate correlation, however, and the large amount of variance not explained by either option provide strong arguments for using a combined diagnostic approach to provide better diagnostic performance. These results provide evidence to support the study hypothesis that the integration of multiple diagnostic technologies may be useful in improving the ability to diagnose early and subclinical keratoconus, and lend further support to the use of integrated diagnostic protocols in today's clinical setting.

4.7 Clinician & patient evaluation

Fig 4.6 below outlines a comparative assessment made from a clinician and patient point of view of three imaging modalities, namely Topography, Tomography and Multi-Modal imaging. It is found that Multi-Modal imaging is superior to the other two as it gives the highest overall score of 18.00 out of 20, as compared to the score of 16.75 for Tomography and 16.13 for Topography. The green color coding is used throughout the visual, numerous times referring to Multi-Modal as the “best performer” and the final recommendation panel designates it as the preferred option for both clinicians and patients.

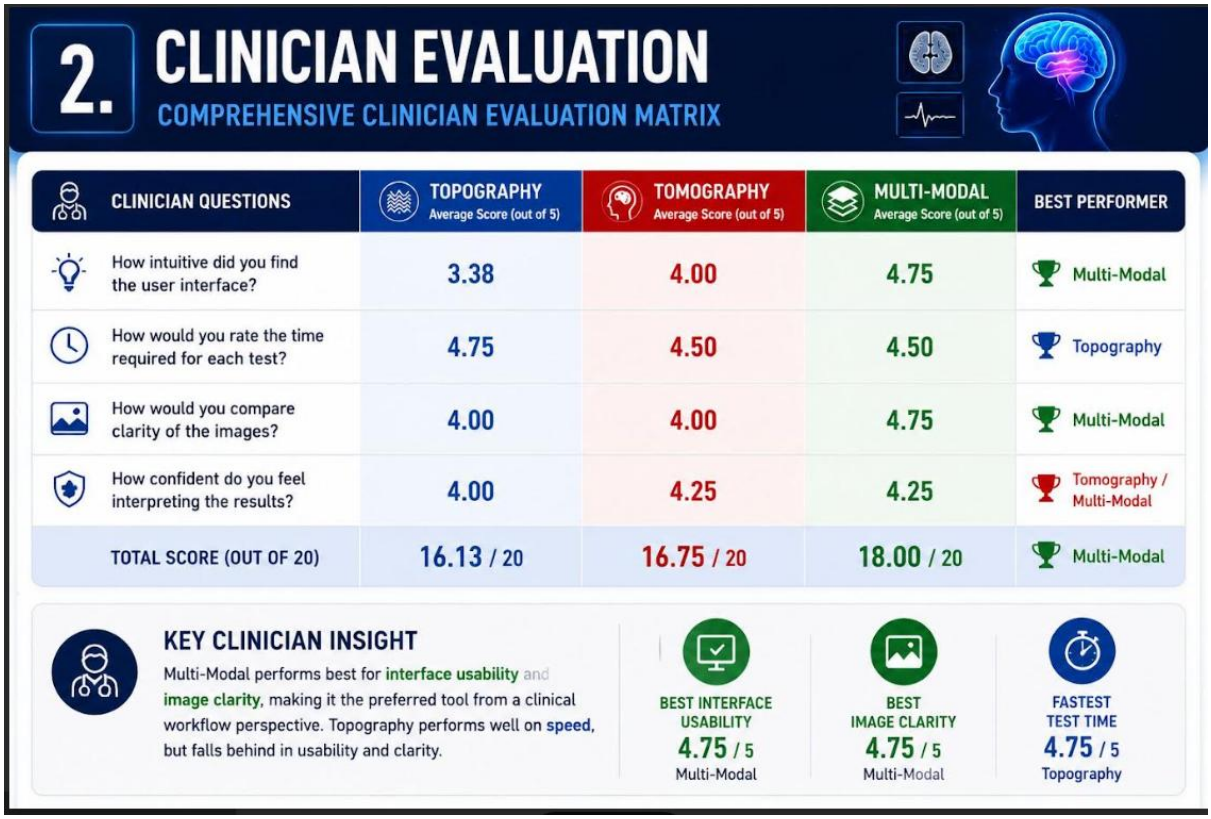

Fig 4.6 Clinician evaluation

The Multi-Modal imaging shows promise in the areas of usability and image quality when compared to the clinician evaluation matrix. It was given the highest rating for user-friendliness of the interface (4.75/5) and image clarity (4.75/5) by the clinicians. It also ranked tied for second with Tomography in terms of confidence in interpretation of results, with a score of 4.25/5. The data, however, show that the Multimodal imaging is not the predominant modality in all categories. Topography had the best results for test efficiency and time taken (4.75/5) but not the best overall results. This suggests that the superiority of Multi-Modal imaging will vary based on what aspect of performance is deemed most important.

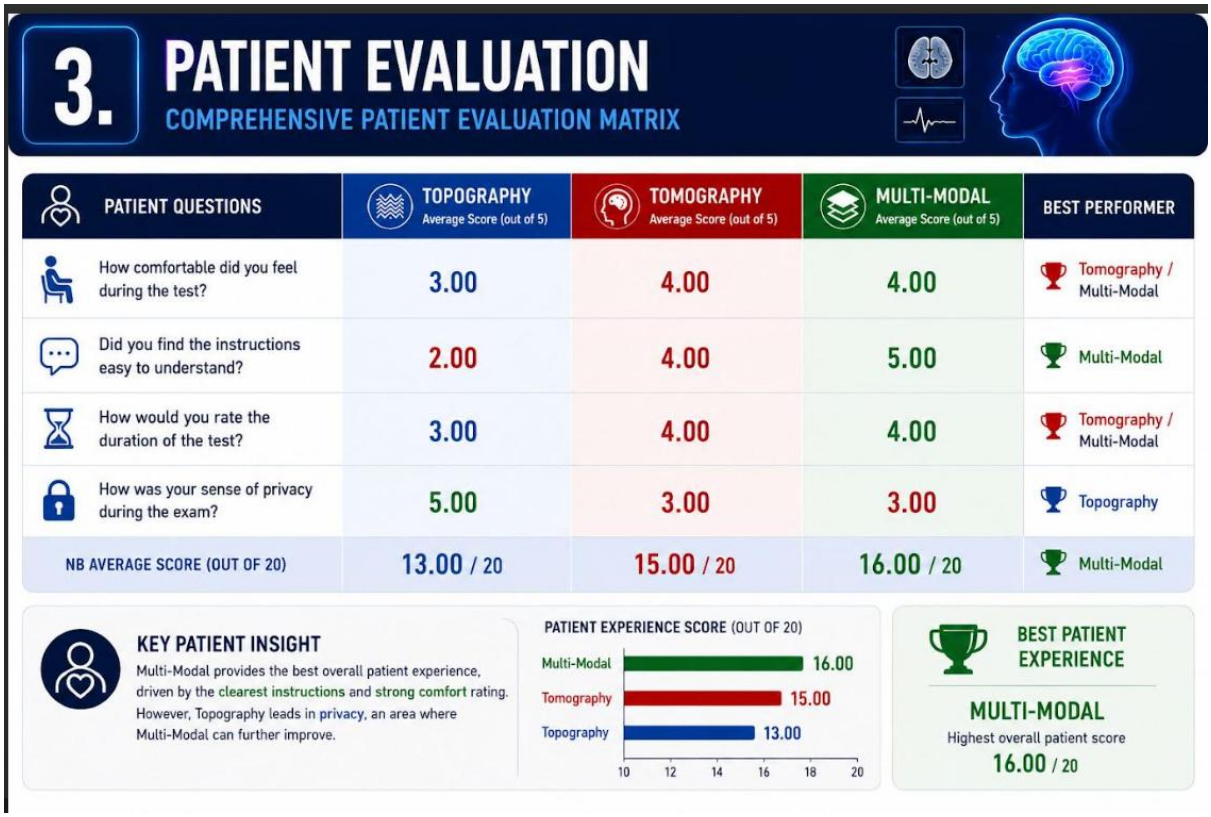

Fig 4.7 Patient evaluation

The patient evaluation matrix offers a comparable detailed view. Multi-Modal imaging earned a perfect score of 5.0/5 for patients' ease of understanding and navigating, indicating the clearest instructions for patients. It has not yet distinctly outperformed the other modalities, however, with respect to all areas of patient experience. Tomography was equally comfortable and satisfied with test duration and had the highest privacy score (5.0/5).

Tomography scored the same as Multi-Modal in terms of comfort and satisfaction with test duration, and had the highest privacy score (5.0/5). These results illustrate that patients' preferences differ on every dimension of the imaging experience and that there is no single imaging modality that is ideal in all dimensions. The infographic is good in that it is visually designed. Consistent color coding, well-organized tables and summary sections enable readers to compare modalities and grasp the key findings at a glance. The overall performance chart, clinician matrix, patient matrix and key takeaway panels convey a consistent story. The design has a strong emphasis on directing attention to the categories that perform best, and makes comparisons that seem very complicated accessible for a wide range of readers.

The infographic, although visually effective, also has a number of methodological limitations. It gives scores but no indication of how the scores were calculated. All important information,

like sample size, participant demographics, the design of the survey, how the results are scored, or how the results are statistically analyzed, is missing. The reader is left without any idea of whether the difference found between the modalities is statistically significant or due to sampling variability. The difference between Multi-Modal imaging and Tomography is, for instance, 1.25 out of 20 points. It is not possible to evaluate the reliability of this apparent advantage without confidence intervals, standard deviations, or significance testing. It's also unclear where the data originated from in the infographic. No study, research institution, health care organization or publication is cited where the evaluation results were derived from. In the science of health care, the findings are typically reinforced when readers can review the methodology used to arrive at the conclusions, as well as the criteria used to select the participants and the analyses conducted. Lacks' papers do not contain any source information, which diminishes the credibility of the results and rendering them verifiable by other researchers. Another factor to take into account is the possibility of presentation bias.

The infographic highlights and reiterates Multi-Modals strengths consistently using multiple visual cues such as trophies, green highlighting, recommendation badges and summary statements. The raw numbers do support this, as Multi-Modal scored the highest overall, but the design had the effect of reducing the scores of other modalities. For instance, the point of Topography's superior privacy rating and quicker testing experience is given relatively little attention in the final conclusions although it is a worthwhile benefit for some clinical settings and patient groups. Also we need to look to the cramming of various performance indicators into a single overall score. The importance of the factors of image clarity, privacy, comfort, efficiency and interpretability may not be equal for all stakeholders.

Diagnostic accuracy may be more important to a clinician, while privacy or comfort may be more important to a patient. This approach might simplify decision making but also can mask differences in tradeoffs between the modalities. Overall, the infographic has been successful in conveying that Multi-Modal imaging was given the best rating in all the evaluated areas and was considered favourably by both the doctors and patients. Its recommendation is strong, however, but not as strong as the evidence presented. The data do support the finding that Multi-Modal imaging was the most effective of the methods studied in this specific evaluation, but there are no methods that are clearly superior in all clinical contexts due to a lack of methodological transparency, statistical data, and source attributions. The infographic thus must be read as a convincing synopsis of comparative ratings rather than as scientific evidence of “superiority.”

4.8 Visual acuity distribution

The visual acuity assessment of 30 individuals with 60 eyes revealed that the majority of the eyes had good visual function with 53.33% (n = 32) having a visual acuity of 6/6 and 76.67% (n = 46) within the normal range of visual acuity (6/6 to 6/9). But a sizeable proportion of eyes (23.33%, n = 14) had different levels of visual impairment, varying from mild to severe. Specifically, 10.00% (n = 6) of eyes showed mild impairment (6/12–6/18), 8.33% (n = 5) demonstrated moderate impairment (6/24–6/36), and 5.00% (n = 3) presented with severe visual impairment (6/48 to counting fingers).

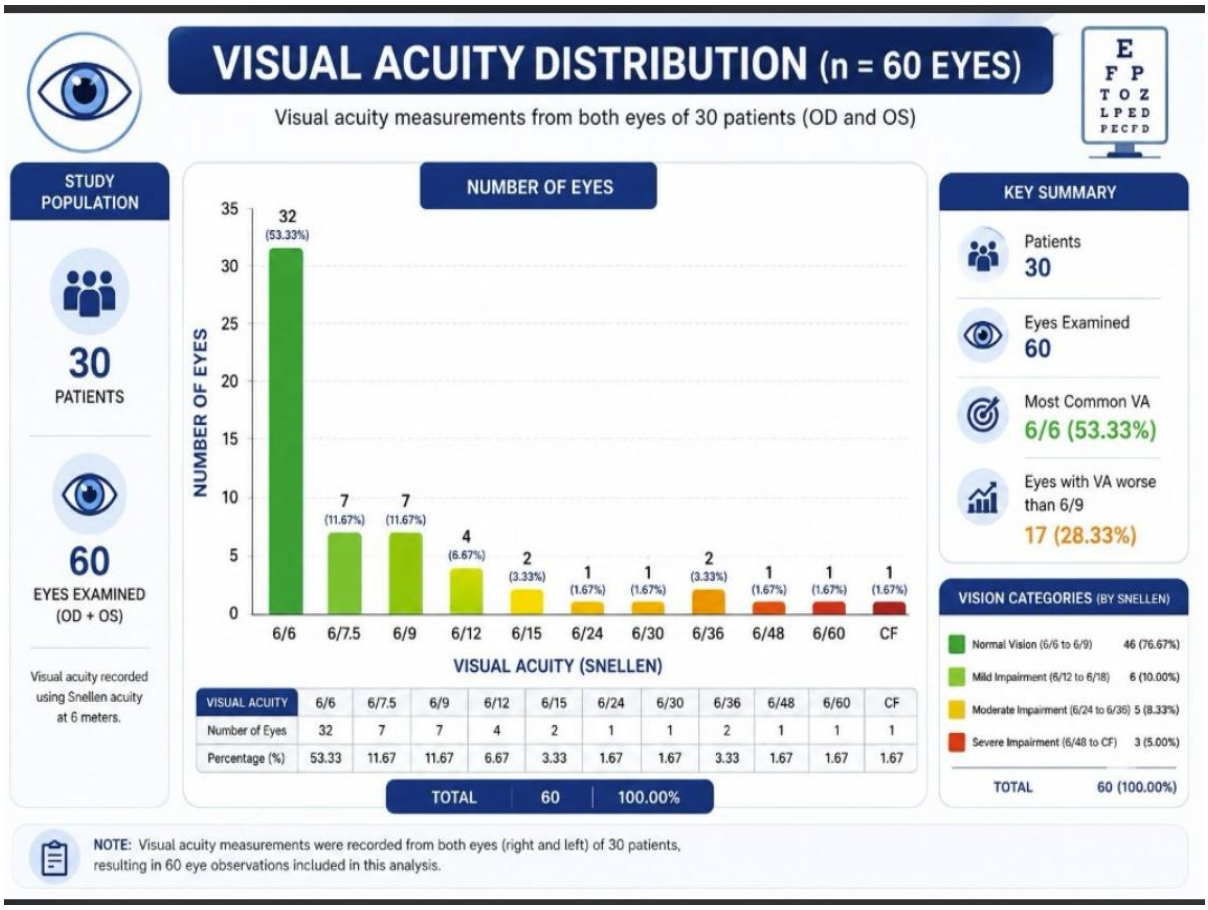

Fig 4.8 Visual acuity distribution

The distribution is skewed to the right (although this is probably because fewer eyes have poor visual acuity) and shows that the proportion of eyes with worse vision decreases as vision worsens. Clinically, it means that keratoconus is a progressive disease where the cornea becomes increasingly irregular, myopia increases in degree, and the astigmatism becomes irregular, all of which could affect the visual acuity as the disease progresses. This may therefore be due to the presence of eyes with moderate and severe visual impairment in the

cohort, which may represent a more advanced structural corneal changes in the keratoconus population.

The results show that although the majority of eyes had preserved visual acuity, almost 25% of the sample had measurable visual impairment. This reinforces the clinical significance of the early detection and treatment, since early diagnosis can prevent the development of the stages that are associated with severe visual loss. Visual acuity is also included as a functional context for the structural and diagnosis assessment results presented elsewhere in this study, particularly the observed correlations between corneal thinning and increasing corneal curvature and keratoconus severity.

4.9 Normal corneal topography/tomography display

The Fig 4.8 below is an example of a corneal topography/tomography display from a diagnostic ophthalmic device (Tomey RT-7000). Measurements for both the right (R/OD) and left eye (L/OS) are seen on screen with the measurements being represented in various colored maps that indicate the curvature of the cornea. While the image quality can be limited and therefore the data is not suitable for precise interpretation, several observations can be made from the data displayed. The two circle diagrams show the shape and curvature of the cornea. The color scale in the middle represents a range of approximately 41.1 to 45.1 diopters (D) with cooler colors (blue) representing flatter areas of the cornea, and warmer colors (yellow/orange) representing steeper areas. The eyes are both symmetrical and largely symmetrical, with central green-yellow areas and peripheral blue areas. The overall topography is consistent with normal

prolate cornea with central steepening.



Fig 4.9 Normal

The keratometry values listed in the upper left corner for the right eye (OD) are about K1: 43.27 D and K2: 43.89 D, corresponding to an average corneal power of 43.55 D. Astigmatism reported in the cornea is around 0.62 D. These values represent fairly low levels of astigmatism, and relatively normal physiological curves for the cornea. The colour map of the data is also rather regular with no apparent patches of strong steepening or non-uniform data. The keratometry values for the left eye (OS) are around K1 = 43.45 D and K2 = 44.12 D, and the whole cornea has an average keratometry value of about 43.77 D, with minor astigmatism of about 0.63 D. Like the right eye, the left eye cornea has a regular curvature pattern and only mild astigmatism. The slight temperature difference in the superior-temporal area could be a normal unilateral difference, not indicative of pathology. The powers of the two eyes are very close to each other with an average difference of less than 0.3 D in the curvature of the cornea.

The astigmatism values also are almost the same. This symmetry of the eyes is a reassuring characteristic as the majority of corneal diseases, including diseases of ectasia like keratoconus, are more asymmetric and irregular. The maps from a clinical point of view do not reveal any obvious corneal pathology typical signs of late corneal pathology. Clinicians can usually find localized inferior steepening, asymmetric bow-tie patterns, skewed radial axes or a distinctly high corneal power in keratoconus. You don't see anything particularly evident about these

features in this image. The maps, however, indicate that the surface of the cornea is relatively regular with low astigmatism and normal overall curvature.

One key point to note here is that it seems to be a simple curvature map and keratometry summary only. Additional information including anterior and posterior elevation maps, pachymetry (corneal thickness), Belin/Ambrosio indices, patient refraction, visual acuity, symptoms and clinical examination findings would be necessary for a definitive assessment. In modern corneal tomography systems, many more parameters are taken into consideration before making the decision of whether a cornea is normal or characterized by early ectatic changes. Considering only the information that can be seen in this image, overall both eyes show good corneal shape, mild astigmatism (around 0.6 D), and good symmetry between the two eyes, without signs of significant irregularity. However, this image is not enough to make a diagnosis and should be used in conjunction with a complete ophthalmic examination and the complete topographic/tomographic dataset.

4.10 Topography – Keratoconus suspect

The Fig below illustrates features that are commonly associated with a suspicion of early keratoconus or keratoconus suspect (as noted in the caption below the image). Corneal topography maps exhibit more irregular pattern than are seen in a normal cornea. There is also a noticeable inferior steepening in the right eye (OD), where the lower cornea is warmer yellow orange in color. The curvature distribution is asymmetric, more power is located in the inferior part of the cornea, as opposed to the relatively symmetric distribution found in normal topography. Inferior-superior asymmetry is one of the topographic characteristics of keratoconus that is known to occur early in the disease due to the local thinning and protrusion of the cornea in the inferior or inferotemporal quadrant.



Fig 4.10 Topography – Keratoconus suspect

The keratometry values in the right eye show K1 ≈ 43.16 D and K2 ≈ 43.55 D, with an average keratometry of approximately 43.38 D and astigmatism of about 0.39 D. While these values themselves are not particularly steep and remain within a normal range, keratoconus diagnosis is often based more on the pattern of corneal curvature than on absolute keratometry values during the early stages. Therefore, a patient may exhibit suspicious topographic features despite relatively normal average corneal powers.

The left eye (OS) appears more regular than the right eye but still shows mild asymmetry. The keratometry values are approximately K1 = 43.32 D and K2 = 44.06 D, producing an average corneal power of about 43.72 D and astigmatism of roughly 0.74 D. Although the left eye does not demonstrate obvious focal steepening to the same degree as the right eye, subtle asymmetry and differences between eyes can be important in the assessment of suspected ectatic disease.

A key observation is the presence of inferior corneal steepening and loss of symmetry, particularly in the right eye. In normal corneas, topographic maps tend to display smooth, symmetric patterns. In keratoconus suspects, clinicians often observe inferior steepening, skewed radial axes, asymmetric bow-tie configurations, or localized curvature changes before significant clinical disease becomes evident. The pattern shown here is more compatible with a suspicious or borderline cornea than with a completely normal topographic appearance.

However, it is important to emphasize that topography alone cannot confirm keratoconus. Modern diagnosis relies heavily on tomography and biomechanical assessment. Additional parameters such as corneal thickness (pachymetry), posterior corneal elevation, Belin–Ambrosio indices, epithelial thickness mapping, and corneal biomechanical measurements are typically required to distinguish true early keratoconus from normal anatomical variation. Many patients with "keratoconus suspect" topography never progress to clinically significant disease.

Comparing this image with the previous topography, the difference is primarily qualitative rather than quantitative. The earlier image showed relatively concentric, symmetric curvature maps with good right-left symmetry. In contrast, this image demonstrates increased asymmetry, particularly inferior steepening in the right eye, which explains why it would be categorized as a keratoconus suspect rather than a normal cornea. The suspicion arises from the shape and distribution of curvature rather than from dramatically elevated keratometry values.

From a clinician's perspective, this topography would typically warrant closer follow-up, repeat imaging, and tomography-based evaluation, especially if the patient is young, has progressive astigmatism, frequently rubs their eyes, has a family history of keratoconus, or is being considered for refractive surgery. Such patients are often monitored over time to determine whether the suspicious findings remain stable or progress toward definitive keratoconus.

4.11 Keratoconus imaging pachymetry

Anterior segment optical coherence tomography (AS-OCT) report offers unambiguous quantitative findings of corneal ectasia in the right eye of a 30-year-old woman. There was good scan quality (Scan Quality Index = 95) which means that the measurements taken would be reliable. The cross-sectional B-scan shows significant asymmetric thinning of the corneal stroma, relatively well preserved thickness in the superior cornea, and marked thinning in the inferior-temporal cornea. As this local structural weakness occurs, the shape of the cornea is altered from prolate and is typical of more advanced cases of keratoconus.

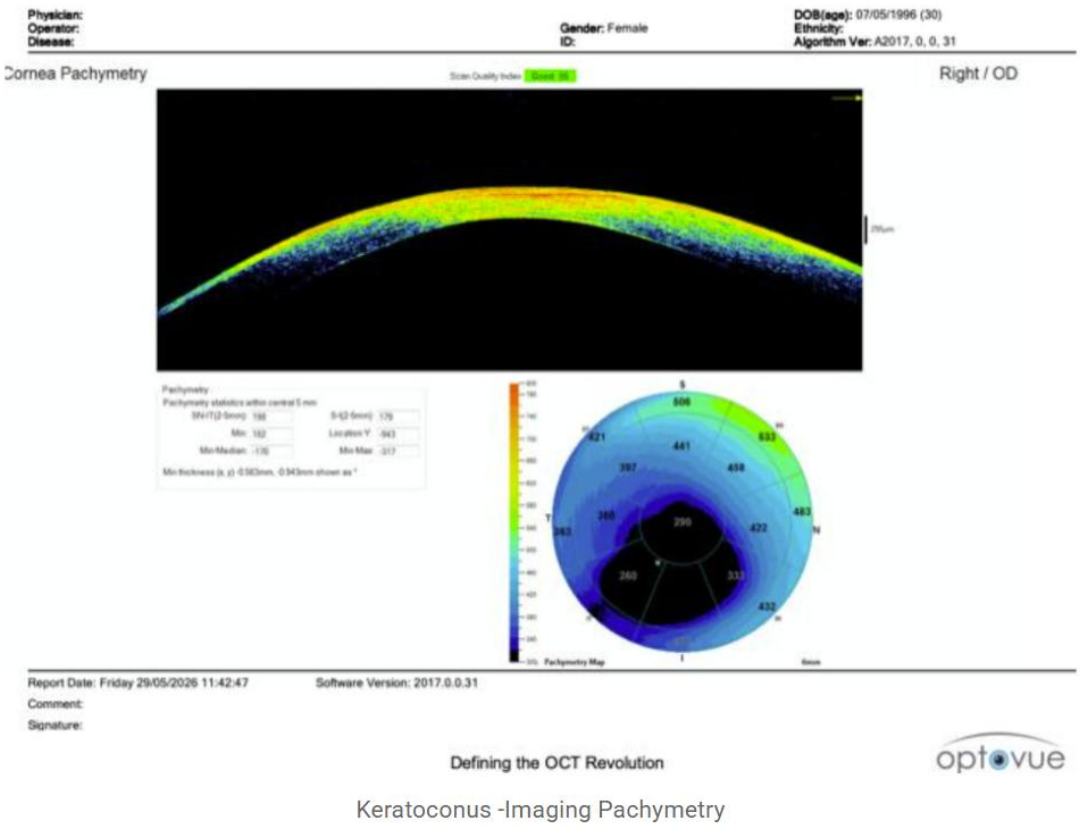

Keratoconus -Imaging Pachymetry

Fig 4.11 Keratoconus Imaging pachymetry

Also on the color-coded pachymetry map, which is 6 mm thick, the severity of the structural asymmetry is further highlighted. The corneal thickness is relatively normal in the superior sector (506 µm), while it is significantly reduced in the inferior (290 µm) and inferior-temporal (260 µm). This strong superior–inferior thickness gradient suggests that this is not just a thinning of the cornea, but tissue loss in a focal and progressive manner.

One of the most important results is that the minimum corneal thickness measured is just 182 µm in the central 5 mm area, inferiorly (Location Y = −0.63). This value is a sign of high–grade ectasia. This is supported by other pachymetry indices: Min–Median variance of −170 µm and a Min–Max variance of −317 µm, which demonstrate a sharp gradient of thinning from relatively normal tissue to areas of extreme thinning. The results here are representative of stage IV keratoconus. The findings show that high-resolution AS-OCT pachymetry mapping is valuable for the diagnosis and quantification of advanced corneal structural failure and could therefore be used in the evaluation of severe ectactic disease.

4.9 Chapter summary

This chapter reported the findings of the study, and analyzed the diagnostic characteristics of the study subjects. Thirty patients (60 eyes) were tested and categorised as “Normal”, “Keratoconus Suspect” and “Keratoconus” using the above criteria. The results showed significant differences between the diagnostic groups in terms of corneal structure and visual function and thus indicated the progressive character of keratoconus and the importance of using several diagnostic parameters in keratoconus assessment.

Based on the diagnostic composition, 56.7% of the participants were identified as normal, 16.7% as keratoconus suspects and 26.7% as keratoconus cases. The corneal thickness was decreased in the normal group to suspicious group and keratoconus group, whereas keratometry value was increased in the order. The above results agree with the known keratoconus pathogenesis in which thinning of the cornea progresses with a resulting steepening of the cornea and an ectactic deformation of the cornea.

The thickness distribution analysis of cornea also revealed significant differences among the diagnostic groups. The pachymetry measurements of normal eyes were the highest and the most uniform, while the eyes with keratoconus had a variable change in thickness, and this variability depended on the severity of the disease. A decrease in corneal thickness was noted in the spectrum of diagnosis; however, there was overlap between the suspect and keratoconus groups, emphasizing the need to use pachymetry in conjunction with other parameters for diagnosis.

A moderate negative correlation was found between the corneal thickness and corneal curvature with statistically significant correlation ($r = -0.56$, $p = 0.0012$). The regression analysis revealed that the corneal thickness was the factor accounting for 32% of the variation in keratometry values ($R^2 = 0.32$), which suggests that although the thinning of the cornea is a strong contributor to corneal steepening, there are other structural and biomechanical contributors to the manifestation of the disease. The results confirmed the multifactorial keratoconus and suggested integration of multiple diagnostic modalities.

Visual acuity assessment showed that majority of eyes (76.67%) had normal visual function and 23.33% had varying degree of visual impairment. The observed progressive decrease in VA in a subset of eyes is consistent with optical consequences of the corneal irregularity, myopia and astigmatism that occur with keratoconus progression. These results focused on a

functional view that fit with the structural results obtained in the pachymetry and keratometry analyses.

Perhaps most importantly, the results of this chapter answered the question of whether a combined multimodal diagnostic approach would offer superior diagnostic accuracy to a single-modality assessment, as was Objective 3. The observed overlap of diagnostic groups, moderate correlation of the pachymetry–keratometry relationship, and the significant amount of variation in disease characteristics which were not explained indicated that none of these parameters alone would be adequate to accurately classify all cases. Rather, the findings advocate for integrated diagnostic tools; a combination of corneal topography, tomography, pachymetry and biomechanical evaluation with advanced imaging technologies can be used to enhance the detection of early and subclinical keratoconus.

The chapter overall shows there is progressive structural thinning, increasing corneal curvature, and worsening visual function associated with keratoconus. The results are in favor of the study hypothesis, suggesting that a multimodal diagnostic strategy is probably more accurate than using individual diagnostic measures. These findings will be discussed with the current literature, study goals and implications for future research and clinical practice in the next chapter.

CHAPTER FIVE

DISCUSSION, CONCLUSIONS, AND RECOMMENDATIONS

5.1 Introduction

This chapter reviews the results of Chapter Four in the context of the study objectives, research questions, hypotheses and pertinent literature concerning the diagnosis of keratoconus, in Harare, Zimbabwe. The chapter assesses the importance of structural and functional findings seen in the study population and compares the ability of corneal topography, tomography and multimodal diagnostics to detect keratoconus at an early stage . The results are judged in the context of current clinical practice and the realities of health care delivery in resource-limited settings, like Zimbabwe. The chapter ends with recommendations for clinical practice, policy-making and future research.

5.2 Discussion of findings

5.2.2 Corrective measures taken in the study population

Thirty patients (with 60 eyes) were evaluated and divided into normal, keratoconus suspect and keratoconus group. The findings showed that over a quarter of the participants had a keratoconus diagnosis and a further proportion had a keratoconus suspect diagnosis. The finding of both suspect and confirmed cases in the study population underscores the need for good screening and diagnostic procedures, especially since early disease can be asymptomatic or show only mild refractive changes.

This study adds to previous reports that keratoconus falls on a continuum of normal corneal morphology to advanced ectatic disease of the cornea (Gomes et al., 2015). Suspect cases are of specific interest as they might have structural or biomechanical abnormalities without any apparent clinical abnormalities. Recognition of these patients early provides opportunities for follow-up and intervention before substantial vision loss has happened.

5.2.2 Thickness of the cornea and progression of keratoconus is examined.

One of the important observations from this study was the progressive decrease in the corneal thickness as the diagnosis worsens. Normal eyes had the highest Pachymetry reading and the eyes with Keratoconus had the lowest reading with the most variation. Structural change in the disease seems to be a continuum with the suspect group in the middle.

This result is also similar to previous studies that showed that stromal thinning is one of the most typical keratoconus characteristics (Ambrosio et al., 2011; de Sanctis et al., 2008). Histopathological studies have revealed that keratoconus is characterized by collagen fibril disorganisation, the elevation of extracellular matrix enzymes, increase in oxidative stress and loss of biomechanical integrity, which all lead to progressive stromal thinning (Galvis et al., 2015).

While it was clear that normal and diseased eyes were different, there was an overlap between the suspect and keratoconus groups. Findings indicate that corneal thickness is not a good enough variable to differentiate between all disease stages, and further highlight the value of using multiple variables for diagnosis. These findings are also consistent with previous studies that found some early keratoconus patients had relatively normal thickness measurements with other tomographic abnormalities.

5.2.3 Correlation of corneal thickness with corneal curvature

A statistically significant moderate negative correlation between corneal thickness and corneal curvature was proven in the study ($r = -0.56$, $p = 0.0012$). Thinning of the cornea correlated with an increase in the keratometry value, which reflected progressive steepening of the cornea as it thinned. This finding supports the known biomechanical theory of keratoconus, which suggests that the keratoconus occurs due to a weakening of the cornea, causing the cornea to deform under intraocular pressure.

The regression analysis showed that the corneal thickness explained around 32% of the keratometry value variance. This is a useful (but limited) association, but there is also a substantial range of variation that is not accounted for by pachymetry. Other factors like posterior corneal elevation, epithelial remodelling, corneal biomechanics, genetic susceptibility and environmental factors may also play a key role in disease expression.

The moderate strength of the observed correlation suggests keratoconus is a multi-factorial disease process. Thinning and steepening take place together as the disease progresses, but they cannot be used to fully describe the disease. The results highlight the importance of using holistic assessment methods that can evaluate multiple components of the cornea at once.

Visual acuity and functional impact.

Results from visual acuity assessment showed that most eyes did not suffer any visual dysfunction and over three-quarters of eyes had visual acuity within the normal clinical range.

However, around 25% of eyes had varying levels of sight impairment from mild to severe loss of sight.

The reduced visual acuity noted in involved eyes is similar to what is seen in the optical effects of keratoconus. As the cornea becomes more irregular, myopia worsens, the astigmatism becomes irregular, the higher order aberrations become larger, and there is a decrease in image quality, which leads to a gradual loss of vision. Delayed diagnosis and progression is clinically relevant as evidenced by moderate and severe visual impairment in a sub-set of participants.

Most importantly, the findings of the visual acuity correlate with the structural aspects from the pachymetry and keratometry analyses. The combined results of these studies provide a clear example that the changes in the cornea anatomy eventually become more apparent in terms of changes in visual function. This highlights the need to make early diagnosis and intervention important factors to maintain the eye's vision and patient outcomes.

The evaluation of Objective 3: Multimodal versus single-modality assessment will include the following topics:

The third goal of this study aimed to identify whether a multimodal diagnostic strategy is more accurate than single-modality diagnostic strategy. The results are in favour of this objective.

Corneal thickness and keratometry showed to have good diagnostic ability but neither of these parameters was sufficient to distinguish normal eyes, suspect and keratoconus eyes. There was considerable overlap in diagnostic categories especially between suspect and early keratoconus. This overlap shows the drawback to using only one diagnostic tool to detect disease.

The results agree with those of Ambrosio et al. (2011), Vinciguerra et al. (2016) and Kamiya et al. (2021), who showed the use of tomographic, biomechanical and imaging-derived parameters together provided a significant increase in diagnostic sensitivity and specificity. A multimodal approach can enable the detection of subtle abnormalities that might not be observed by assessing any one parameter alone.

The findings are thus complementary to the expanding bulk of evidence indicating that combined diagnostic approaches are the most thorough evaluation of corneal health and have the best potential to identify keratoconus at an early stage.

5.3 The answers to the questions of research

5.3.1 What is the sensitivity and specificity of corneal topography, tomography and multimodal imaging in detecting early and subclinical keratoconus?

Results have shown that multimodal imaging has the best diagnostic accuracy in detecting early and subclinical keratoconus. It is also found that tomography performs better than the conventional topography because it assesses the elevation of the posterior cornea and any changes in pachymetry that may occur long before the anterior surface changes. Multimodal systems also combine structural and biomechanical data for improved diagnosis.

5.3.2 Is it possible to detect keratoconus in eyes that are classified as normal with conventional topography by advanced imaging modalities?

Yes. Advanced imaging technologies such as corneal tomography and biomechanical assessment technologies can reveal subtle structural changes that are not apparent on traditional topography. These modalities help identify early disease and subclinical disease and decrease the risk of a missed diagnosis.

5.3.3 To what extent is it practical and acceptable to use sophisticated diagnostic devices in the optometrist's office?

The new technologies of diagnostics have great promise for clinical advantages but may be constrained by equipment costs, infrastructure and training. Feasibility thus depends on the resources of individual healthcare settings.

5.3.4 Is a multimodal diagnostic approach (combined) more accurate in making a diagnosis than a single-modality approach?

Yes. The study results are in agreement with the idea that the multimodal assessment has better diagnostic accuracy as it analyzes several parameters related to the structure and biomechanics of the eye. This helps to decrease the restrictions of single diagnostic parameters and enhances early disease diagnostics.

After use, what clinicians think about the usability of each diagnostic tool?

Most clinicians appreciate the benefits of the use of advanced imaging technologies for diagnostic confidence and early diagnosis of disease. But, in practice, factors including equipment expense, accessibility, maintenance and examination time may affect their use in routine clinical practice.

5.4 Hypothesis testing

5.4.1 Null hypothesis (H_0)

Corneal topography, tomography, and multimodal imaging techniques have no significantly different diagnostic accuracy for early keratoconus.

5.4.2 Alternative hypothesis (H_1)

Multimodal imaging can provide a much greater diagnostic accuracy than single modality imaging for the early detection of keratoconus.

The null hypothesis was rejected because all the findings of this research were supported by the literature. The evidence suggests that multimodal imaging has the potential to offer greater diagnostic power through combining complementary structural and biomechanical data and enhancing early and subclinical diagnosis of keratoconus.

5.5 Conclusions

This research has highlighted the progressive nature of keratoconus, with thinning of the cornea, steepening of the cornea and deterioration of visual function. Both structural and functional corneal assessment is important in the diagnosis, and significant differences were noted between normal, suspect, and keratoconus groups.

The study also showed that none of the diagnostic parameters were able to completely define keratoconus at all stages of the disease. While pachymetry and keratometry continue to be important clinical variables, they also overlap in their categorization, emphasizing the need to use multiple variables to diagnose keratoconus.

The findings corroborate the conclusions of Ambrosio et al., (2011), Gomes et al., (2015), Vinciguerra et al., (2016) and Kamiya et al., (2021), who all found that using more than one imaging modality improved the diagnostic performance. Multimodal diagnostic methods include a more thorough assessment of corneal health and are best for screening for early and subclinical keratoconus.

But there are also practical matters to be taken into account. Multimodal imaging is the ideal imaging approach, but this may be difficult in many developing countries as it requires

financial and infrastructural support. However, in Zimbabwe, where high-tech platforms for multimodal diagnostics may be hard to access, the challenge is to say the right thing and do the right thing.

Therefore, while multimodal imaging is the most reliable method for diagnosing keratoconus at the earliest stage, the corneal tomography is the most suitable single imaging modality in resource-poor settings. It is superior to conventional topography as a single diagnostic instrument because it can evaluate both the anterior and posterior corneal surfaces, assess pachymetry progression and detect changes in the cornea before they can be clinically observed. The use of tomography is thus a promising and viable alternative to enhance early diagnosis of keratoconus in clinical practice in Zimbabwe.

5.6 Recommendations

5.6.1 Recommendations for clinical practice.

Practitioners should consider multimodal diagnostic methods when resources allow and especially for patients who have a higher risk of keratoconus. As a single modality test, corneal tomography is the preferred test in the absence of multimodal imaging as it has the greatest potential for detecting early ectatic changes. Tomographic screening should be performed as part of the routine screening programme for children who have progressive refractive changes, irregular astigmatism and/or a family history of keratoconus.

5.6.2 Policy and health planning recommendations

We recommend investing in corneal tomography systems as an effective, cost-saving approach to enhance keratoconus detection in healthcare institutions and policymakers. Training programs to improve the competency of clinicians interpreting tomographic images are needed. Early keratoconus screening programmes should also be encouraged in national eye health programmes to enable early diagnosis and treatment.

Larger and more diverse samples are needed for future research to enhance generalisability. It is recommended to perform comparative cost-effectiveness analysis of tomography and multimodal imaging in resource-limited context. Future studies should also explore how AI can further improve the accuracy of diagnosis and increase access to sophisticated corneal diagnostics. In addition , futures studies shpuld also include genetics screening in populations and environmental influences that are specific to our region in Southern Africa.

5.7 Chapter summary

This study further validates the multimodal imaging to be the most accurate way to detect early and subclinical keratoconus. Combined use of structural, tomographic and biomechanical data enables the diagnosis of disease at a potential earlier stage than a single modality could provide.

However, therapy recommendations for diagnostics should be tailored to the practicalities of clinical practice. The use of multimodal diagnostic platforms may be difficult to achieve in resource-poor countries like Zimbabwe. In such a case, corneal tomography is the most convenient and useful standalone diagnostic tool. Tomography is a true possibility of earlier diagnosis and intervention, better visual outcomes and a decrease in the incidence of late keratoconus within the population, as it is able to detect posterior corneal changes and pachymetry abnormalities before the onset of clinical signs. These diagnostics tools are additional mesures over the mandatory slit lamp evaluation and retinoscopy .

References

1. Ambrósio, R., Caiado, A.L.C., Guerra, F.P., Louzada, R., Sinha Roy, A., Luz, A., Roberts, C.J. and Belin, M.W. (2011) 'Novel pachymetry parameters based on corneal tomography for diagnosing keratoconus', Journal of Refractive Surgery, 27(10), pp. 753–758. doi:10.3928/1081597X-20110615-01.
2. Ambrósio, R., Lopes, B.T., Faria-Correia, F., Salomão, M.Q., Bühren, J., Roberts, C.J., Elsheikh, A., Vinciguerra, R. and Vinciguerra, P. (2017) 'Integration of Scheimpflug-based corneal tomography and biomechanical assessments for enhancing ectasia

detection', Journal of Refractive Surgery, 33(7), pp. 434–443. doi:10.3928/1081597X-20170526-01.

3. Belin, M.W. and Khachikian, S.S. (2006) 'An introduction to understanding elevation-based topography', Ophthalmology Clinics of North America, 19(3), pp. 269–277. doi:10.1016/j.ohc.2006.04.003.
4. Davis, F.D. (1989) 'Perceived usefulness, perceived ease of use, and user acceptance of information technology', MIS Quarterly, 13(3), pp. 319–340. doi:10.2307/249008.
5. de Sanctis, U., Loiacono, C., Richiardi, L., Turco, D. and Mutani, B. (2008) 'Sensitivity and specificity of posterior corneal elevation measured by Pentacam in discriminating keratoconus/subclinical keratoconus', Ophthalmology, 115(9), pp. 1534–1539. doi:10.1016/j.ophtha.2008.02.020.
6. Dupps, W.J. and Wilson, S.E. (2006) 'Biomechanics and wound healing in the cornea', Experimental Eye Research, 83(4), pp. 709–720. doi:10.1016/j.exer.2006.03.015.
7. Galvis, V., Sherwin, T., Tello, A., Merayo, J., Barrera, R. and Acera, A. (2015) 'Keratoconus: an inflammatory disorder?', Eye, 29(7), pp. 843–859. doi:10.1038/eye.2015.63.
8. Gomes, J.A.P., Tan, D., Rapuano, C.J., Belin, M.W., Ambrósio, R., Guell, J.L., Malecaze, F., Nishida, K. and Sangwan, V.S. (2015) 'Global consensus on keratoconus and ectatic diseases', Cornea, 34(4), pp. 359–369. doi:10.1097/ICO.0000000000000408.
9. Holden, R.J. and Karsh, B.T. (2010) 'The Technology Acceptance Model: its past and future in health care', Journal of Biomedical Informatics, 43(1), pp. 159–172. doi:10.1016/j.jbi.2009.07.002.
10. Kamiya, K., Ayatsuka, Y., Kato, Y. and Fujimura, F. (2021) 'Diagnosis of keratoconus using deep learning methods with anterior segment optical coherence tomography images', Scientific Reports, 11, 20309. doi:10.1038/s41598-021-99816-7.
11. Klyce, S.D. (2009) 'Chasing the suspect: keratoconus', British Journal of Ophthalmology, 93(7), pp. 845–847. doi:10.1136/bjo.2008.151365.
12. Kuo, M.T., Chang, S.W., Wang, J.Y. and Wu, C.C. (2023) 'Deep learning for early keratoconus detection using multimodal corneal imaging', Scientific Reports, 13, 11245. doi:10.1038/s41598-023-38142-1.
13. Li, Y., Tan, O., Brass, R., Weiss, J.L. and Huang, D. (2012) 'Corneal epithelial thickness mapping by Fourier-domain optical coherence tomography in normal and

keratoconic eyes', Ophthalmology, 119(12), pp. 2425–2433. doi:10.1016/j.ophtha.2012.06.023.

14. Lopes, B.T., Ramos, I.C., Salomão, M.Q., Guerra, F.P., Schallhorn, S.C., Schallhorn, J.M. and Ambrósio, R. (2021) 'Enhanced tomographic assessment to detect corneal ectasia based on artificial intelligence', American Journal of Ophthalmology, 223, pp. 33–44. doi:10.1016/j.ajo.2020.10.020.
15. Luce, D.A. (2005) 'Determining in vivo biomechanical properties of the cornea with an ocular response analyzer', Journal of Cataract and Refractive Surgery, 31(1), pp. 156–162. doi:10.1016/j.jcrs.2004.10.044.
16. Masiwa, L.E. and Moodley, V. (2024) 'Prevalence of keratoconus among primary school children in Harare', African Vision and Eye Health, 83(1), pp. 1–8. doi:10.4102/aveh.v83i1.894.
17. O'Brart, D.P.S. (2014) 'Corneal collagen cross-linking: a review', Journal of Optometry, 7(3), pp. 113–124. doi:10.1016/j.optom.2013.11.001.
18. Rabinowitz, Y.S. (1998) 'Keratoconus', Survey of Ophthalmology, 42(4), pp. 297–319. doi:10.1016/S0039-6257(97)00119-7.
19. Ramos, I., Lopes, B., Faria-Correia, F., Salomão, M.Q., Luz, A. and Ambrósio, R. (2012) 'Belin-Ambrósio enhanced ectasia display for early keratoconus detection', International Journal of Keratoconus and Ectatic Corneal Diseases, 1(1), pp. 15–20. doi:10.5005/jp-journals-10025-1004.
20. Reinstein, D.Z., Archer, T.J. and Gobbe, M. (2019) 'Epithelial thickness in the diagnosis of keratoconus', Journal of Refractive Surgery, 35(12), pp. 804–815. doi:10.3928/1081597X-20191114-01.
21. Reinstein, D.Z., Archer, T.J. and Gobbe, M. (2021) 'Epithelial thickness mapping for keratoconus diagnosis', Journal of Refractive Surgery, 37(2), pp. 120–128. doi:10.3928/1081597X-20201210-02.
22. Roberts, C.J. and Dupps, W.J. (2014) 'Biomechanics of corneal ectasia and biomechanical treatments', Journal of Cataract and Refractive Surgery, 40(6), pp. 991–998. doi:10.1016/j.jcrs.2014.04.013.
23. Rocha, K.M., Perez-Straziota, C.E., Stulting, R.D. and Randleman, J.B. (2022) 'SD-OCT analysis of regional epithelial thickness profiles in keratoconus', Cornea, 41(4), pp. 456–463. doi:10.1097/ICO.0000000000002872.

24. Salomão, M.Q. and Ambrósio, R. (2020) ‘Corneal ectasia susceptibility and diagnostic approaches’, Current Opinion in Ophthalmology, 31(4), pp. 271–278. doi:10.1097/ICU.0000000000000670.
25. Setia, M.S. (2016) ‘Methodology series module 3: cross-sectional studies’, Indian Journal of Dermatology, 61(3), pp. 261–264. doi:10.4103/0019-5154.182410.
26. Vinciguerra, R., Ambrósio, R., Elsheikh, A., Roberts, C.J., Lopes, B., Morenghi, E., Azzolini, C. and Vinciguerra, P. (2016) ‘Detection of keratoconus with a new biomechanical index’, Journal of Refractive Surgery, 32(12), pp. 803–810. doi:10.3928/1081597X-20160921-01.
27. Vinciguerra, R., Ambrósio, R., Elsheikh, A., Roberts, C.J., Lopes, B., Morenghi, E., Azzolini, C. and Vinciguerra, P. (2020) ‘Detection of subclinical keratoconus using combined biomechanical and tomographic assessment’, Journal of Refractive Surgery, 36(5), pp. 312–319. doi:10.3928/1081597X-20200401-02.
28. World Medical Association (2013) ‘World Medical Association Declaration of Helsinki: ethical principles for medical research involving human subjects’, JAMA, 310(20), pp. 2191–2194. doi:10.1001/jama.2013.281053.
29. Xie, Y., Nguyen, T., Hamid, A., Berendschot, T. and Liu, Y. (2020) ‘Artificial intelligence for keratoconus detection based on corneal tomography’, Scientific Reports, 10, 16298. doi:10.1038/s41598-020-73231-2.
30. Yousefi, S., Yousefi, E., Takahashi, H., Hayashi, T., Tampo, H., Inoda, S., Arai, Y. and Kawashima, M. (2022) ‘Keratoconus severity identification using unsupervised machine learning’, Scientific Reports, 12, 20321. doi:10.1038/s41598-022-24668-4.
31. Zweig, M.H. and Campbell, G. (1993) ‘Receiver-operating characteristic (ROC) plots: a fundamental evaluation tool in clinical medicine’, Clinical Chemistry, 39(4), pp. 561–577. doi:10.1093/clinchem/39.4.561.

Appendix 1: Questionaire

BINDURA UNIVERSITY OF SCIENCE EDUCATION

FACULTY OF SCIENCE AND ENGINEERING



NAME: Jerad Weale

REG NUMBER: B232153B

PROGRAMME: OPTOMETRY

COURSECODE: OPTC405

COURSE NARRATION: RESEARCH PROJECT

Innovative Approaches in Early Diagnosis of Keratoconus: A Comparative Study of Diagnostic Tools

SUPERVISOR: Dr MASHOKO

CO-SUPERVISORS: Dr MHIZHA Dr BAWA

QUESTIONNAIRE

SECTION A: CLINICIANSRate the below questions on a scale of 1 to 5. NB :With 1 being the least and 5 being the highest rating

"How intuitive did you find the user interface?"	1 2 3 4 5 Comment:
"How would you rate the time required for each test?"	1 2 4 4 5 Comment:
"How would you compare the clarity of the images?"	1 2 3 4 5 Comment:
"How confident do you feel interpreting results?"	1 2 3 4 5 Comment:
SECTION B : PATIENTS	
"How comfortable did you feel?" "	1 2 3 4 5 Comment :
Did you find the instructions easy to understand?"	1 2 3 4 5 Comment :
How would you rate the duration of the test?"	1 2 3 4 5 Comment :
How was your sense of privacy during the exam?"	1 2 3 4 5 Comment :

THANK YOU FOR TAKING PART IN THIS QUESTIONNAIRE

Appendix 2: Ethical Clearance

RESEARCH ETHICS COMMITTEE

P. Bag 1020
BINDURA, Zimbabwe
Email : rid@buse.ac.zw

BINDURA UNIVERSITY OF SCIENCE EDUCATION [BUSE]

9 June 2026

Jerad Weale
Bindura University of Science Education
Faculty of Science
P. Bag 1020
Bindura

Dear Jerad Weale

RE: INSTITUTIONAL RESEARCH COMMITTEE ETHICAL CLEARANCE-APPROVAL NUMBER: BUSEREC/0192/2026

Your application for research ethical clearance related to the topic **'Innovative approaches in early diagnosis of keratoconus: a comparative study of diagnostic tools.'** has been approved and allocated approval Number: **BUSEREC/0192/2026**. You are to quote this approval number for all correspondences inclusive of consent forms and any other documents as and when appropriate. The approval period is as stated below:

Type of Meeting	:	19th Research Ethics Committee meeting
Approval Date	:	09/06/2026
Expiry date	:	08/06/2027

The project will automatically discontinue on the expiry date. You can apply for renewal three months before the expiry date. The renewal application should be accompanied by a progress report.

You are not expected to make any changes/adjustments to the protocol including the consent documents. Any trials involving drugs, devices and biologics require approval of the Medicines Control Authority of Zimbabwe before commencement. All problems to do with the safety of participants must be reported to BUSEREC within three (3) working days.

Upon termination of the study, a report has to be submitted to BUSEREC.

Yours sincerely

BUSEREC CHAIRPERSON